

Lymphatic mapping helps to define resection margins for midgut carcinoids

Yi-Zarn Wang, DDS, MD, Saju Joseph, MD, Erika Lindholm, BSE, John Lyons, MD, J. Philip Boudreaux, MD, and Eugene A. Woltering, MD, New Orleans, LA

Background. *The extensive mesenteric lymphadenopathy associated with midgut carcinoids often causes lymphatic obstruction and leads to the development of alternative lymphatic drainage pathways. We hypothesized that altered lymphatic drainage makes traditional determination of resection margins inadequate.*

Methods. *One hundred and seventy patients underwent cytoreductive surgery for neuroendocrine tumors from November 2006 to August 2008. Forty-nine patients underwent intra-operative lymphatic mapping with lymphazurin dye as a single agent. Twenty-seven patients had midgut primaries. We reviewed operative findings and pathology to evaluate the safety and efficacy of lymphatic mapping for midgut carcinoids. Lymphatic mapping defined resection margins were compared to traditional surgical margins.*

Results. *There were no adverse events associated with the 49 lymphatic mapping procedures. Twenty-five (92%) patients had ileal and 2 had jejunal primaries. Lymphatic mapping changed traditional resection margins in 88% of patients. We preserved the ileocecal valve in 6 of 15 (40%) of patients with terminal ileal primaries.*

Conclusion. *Lymphatic mapping seems to be a safe, time efficient, and effective way to determine adequate resection margins for midgut carcinoids. We advocate using lymphatic mapping for patients with midgut carcinoids to identify adequate resection margins and assist in preservation of the ileocecal valve in patients with terminal ileal primary carcinoids. (Surgery 2009;146:993-7.)*

From the Louisiana State University Health Sciences Center, Department of Surgery, Section of Surgical Oncology and Endocrine Surgery, New Orleans, LA

MIDGUT CARCINOID is an uncommon malignancy with reported incidences of only 1–2 per 100,000 populations per year.¹ It has been estimated the average surgeon only sees 2–3 carcinoid patients before their retirements. The presenting symptoms of midgut carcinoid are usually extremely vague, especially in the early stages of the disease and the diagnosis of most patients with midgut carcinoid is often delayed for years. As a result, midgut carcinoid patients almost always present at an advanced stage. Common intra-operative findings in a midgut carcinoid patient include partial bowel obstruction resulting from the desmoplastic retraction of the bowel down toward the boggy mesenteric lymphadenopathy. This

lymphadenopathy often encases the major mesenteric vessels and this encasement can lead to mesentery ischemia and intestinal angina. Frequently, multiple “primaries” are found within a short segment of the small bowel. The cause of these multiple primaries remains unexplained. There are no treatment options other than surgery for the primary tumor in the small bowel and its associated lymphadenopathy. Many authors advocate aggressive cytoreduction procedures to remove the primary tumor and its associated nodal disease, even in patients with liver metastasis.²⁻⁴ The surgical principles that guide these major cytoreduction procedures mandate careful attention to the adequacy of surgical margins, the resection of the lymphatic drainage bed of the tumor, and preservation of the blood supply to the bowel margins.

Traditionally, the presence of a terminal ileal carcinoid mandates a formal right hemicolectomy or at least a resection of the terminal ileum and a short segment of the cecum. Preservation of the small bowel length and the ileocecal valve in patients suffering from carcinoid syndrome is

Accepted for publication September 17, 2009.

Reprint requests: Yi-Zarn Wang, DDS, MD, 200 West Esplanade, Suite 200, Kenner, LA 70065. E-mail: ywang@lsuhsc.edu.

0039-6060/\$ - see front matter

© 2009 Mosby, Inc. All rights reserved.

doi:10.1016/j.surg.2009.09.005

extremely crucial because it minimizes diarrhea and reduces the incidence of short gut syndrome. In contrast, inadequate resection of the small bowel and its associated mesentery might lead to promulgation of lymphatic tumor emboli and increase local recurrences at or near the bowel resection margins and the adjacent mesentery.

Lymphatic mapping and sentinel lymph node biopsy have become the standard of care in treating patients with breast cancer and melanoma.⁵⁻⁷ The utility of sentinel lymph node procedures in gastrointestinal malignancy has been limited.^{8,9} No data exist on the use of lymphatic mapping in small bowel tumors. To date, there have been no reports on use of lymphatic mapping to direct the resection of small bowel carcinoids.

We first implemented lymphatic mapping in small bowel carcinoid patients in late 2006. Our initial goal was to evaluate the movement of methylene blue dye, injected around the primary tumor, to determine if this technique would help us to understand the limits of lymphatic drainage along the length of the bowel wall. We never intended to perform a sentinel lymph node procedure using this technique because the presence of massive lymphadenopathy in these patients made the use of sentinel node detection of the draining lymph nodes superfluous. Our lymphatic mapping revealed a group of reproducible findings that included boggy mesenteric nodal disease, extensive longitudinal subserosal lymphatic drainage within the small bowel, and the existence of clusters of multiple "primary" tumors in those patients who had the most extensive lymphatic obstruction at the root of the mesentery. In these patients, the obstruction of the lymphatics at the root of the mesentery seemed to drive the tumor-bearing lymph in a longitudinal fashion along the bowel wall. This drainage progressed until an unobstructed lymphatic channel was encountered. At that point, the lymphatic drainage turned in a radial fashion and dove into the mesentery. We hypothesized that boggy lymphadenopathy within the mesentery blocks the normal radial drainage of lymph into the mesenteric lymphatic channels. As a consequence, the lymphatics detour the blockage of the lymphatic channels within the small bowel until it reaches a point where the intermesenteric lymphatic channels remains patent. At this point, the lymph again drains radially. Our hypothesis easily explains why patients with massive lymphadenopathy may have multiple "primaries" and why recurrent carcinoids, treated by traditional resection techniques, are almost always located at or adjacent to the previous resection margins. We

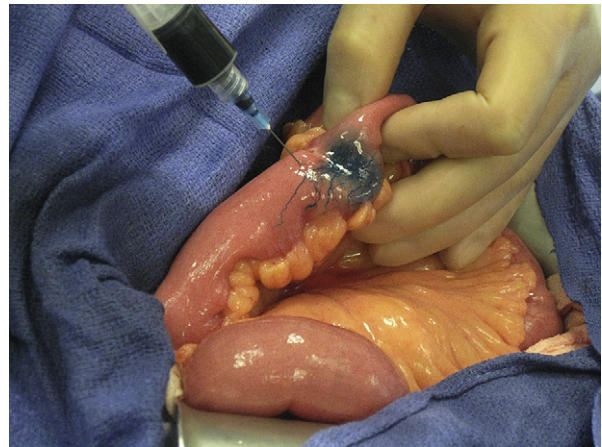


Fig 1. Injection of lymphazurin blue into the primary tumor.

also observed that intra-operative lymphatic mapping accurately demonstrate the altered lymphatic drainage of midgut carcinoids and help the surgeon to more accurately define the resection margins. We believe that in patients with terminal ileal carcinoids, in whom the lymphatic drainage dives into the small bowel mesentery before its longitudinal progress reaches the ileocecal valve, would be candidates for valve preservation rather than radical resection.

In this report, we summarize our intra-operative findings obtained from lymphatic mapping in midgut carcinoid patients and propose a method by which surgeons can better define the resection margins in bowel-based neuroendocrine tumors.

METHODS

Patients undergoing cytoreductive surgery were explored using standard incisions. Adhesions were taken down using a combination of sharp and blunt dissection and the overall tumor burden of the patient was evaluated by 2 experienced senior surgeons. Care was taken to avoid dissection and disruption of the lymphatics of the small bowel before lymphazurin blue injection.

Patients underwent injection of 1–5 cm³ of 1% lymphazurin blue dye (Covidien, Norwalk, CT) in a circumferential pattern into the subserosa (Fig 1). In patients with multiple small bowel tumors, the most proximal, the most distal, and the largest tumors were injected. The dye was allowed to migrate for 10–15 minutes while surgeons were performing cholecystectomy, ultrasound examination of the liver or mobilization of liver for radiofrequency ablation, or resection of liver. The longitudinal and radial progression of the dye was then assessed (Figs 2–4). The cessation of

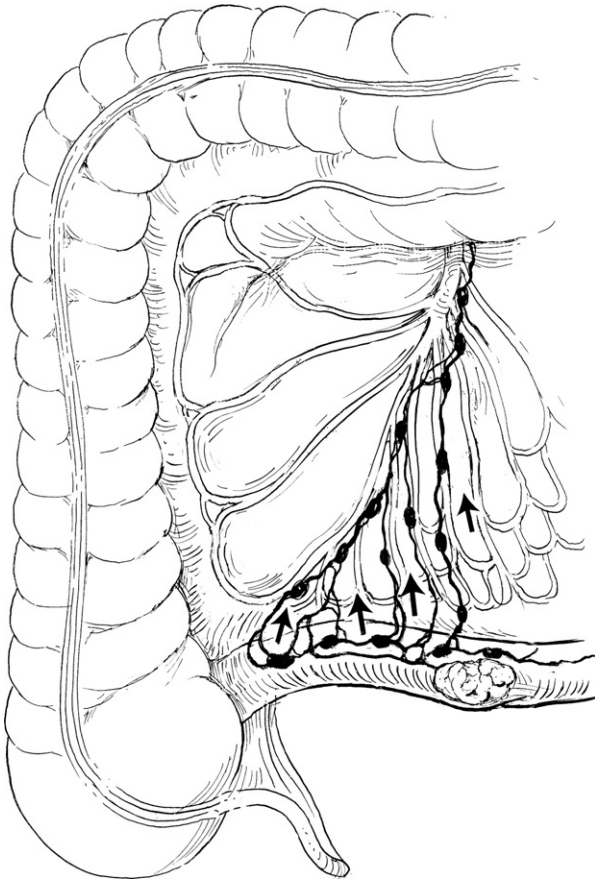


Fig 2. Terminal ileal carcinoid with radial lymphatic drainage proximal to the ileocecal valve.

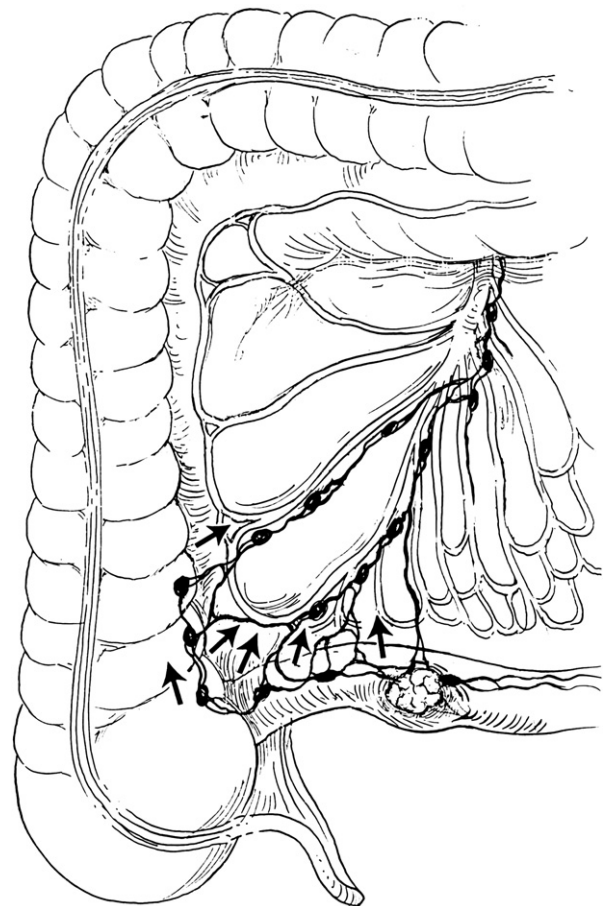


Fig 3. Terminal ileal carcinoid with lymphatic drainage that crosses the ileocecal valve.

proximal dye migration (the point that longitudinal movement of dye ceased and the drainage of the dye began to migrate toward the root of the mesentery in a radial fashion) was used to define the resection margins (Fig 5).

In some cases with terminal ileal primary tumors, the dye was seen to transverse the ileocecal valve, whereas in other cases (40%) the dye drainage pattern moved radially toward the root of the ileal mesentery before it reached the ileocecal valve (Fig 2). In these cases, the line of resection was chosen to preserve the ileocecal valve.

RESULTS

One hundred and seventy patients underwent cytoreductive surgery for neuroendocrine tumors from November 2006 to August 2008. Forty-nine patients underwent intraoperative lymphatic mapping using lymphazurin dye as a single mapping agent. Twenty-seven patients had midgut primaries. Twenty-five (92%) patients had ileal and 2 (8%) had jejunal primaries. Among them, 15 patients had tumors located near the ileocecal

valve that would traditionally require an ileocectomy or a right hemicolectomy. All attempts at mapping were successful.

Patients with boggy nodal metastasis often had multiple primary tumors and long segments of longitudinal subserosal dye movement (Fig 5). Conversely, unobstructed mesenteries were always associated with single primary tumor and much shorter longitudinal dye drainage pattern (Fig 6).

Lymphatic mapping changed the resection margins in 88% of the patients and we were able to preserve the ileocecal valve in 6 of 15 (40%) patients with terminal ileal primaries. There were no adverse events or anaphylactic reactions associated with the 49 lymphatic mapping procedures with lymphazurin blue dye.

DISCUSSION

Lymphazurin blue or methylene blue is commonly used in conjunction with ^{99m}Tc colloid to detect and ultimately to histologically evaluate sentinel lymph nodes. In this large series of cases,

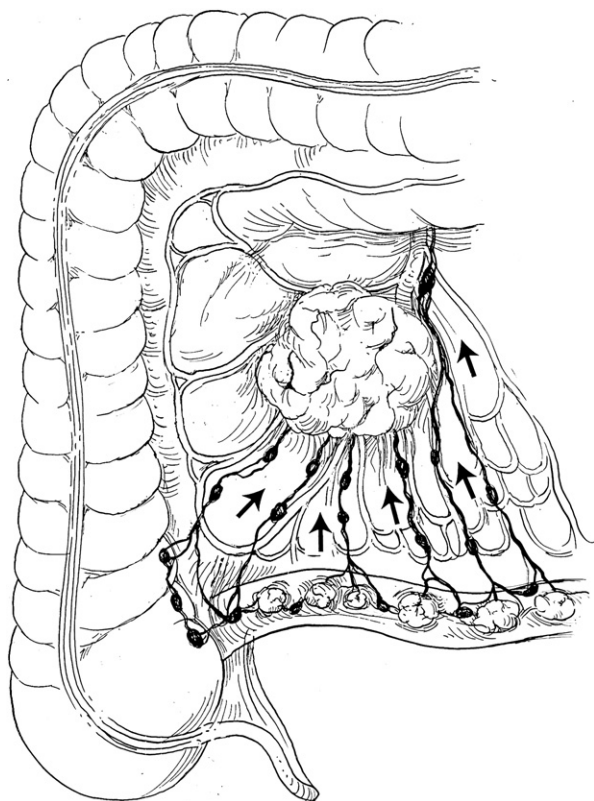


Fig 4. Multiple “drop lesions” and fibrotic mesentery with longitudinal lymphatic drainage.

lymphazurin blue was not used to detect sentinel lymph nodes but rather used to map subserosal lymphatic channels that might carry cancer cells. This report represents the first use of this lymphatic mapping technique to identify adequate margins for surgical resection of midgut carcinoid tumors and to spare the ileocecal valve when conditions permit.

The unexpected intra-operative findings of elongated longitudinal alternative subserosal lymphatic drainage patterns seen in midgut carcinoid patients with multiple small primaries and its associated boggy mesenteric lymphadenopathy have not been previously reported. It seems that the obstructed mesenteric lymphatics drive the lymph drainage of the tumor along the bowel’s subserosal lymphatics in a longitudinal direction. As this lymph travels along the length of the bowel, it finally reaches an unobstructed lymphatic and then turns radially toward the root of the mesentery (Fig 2). Conceivably during this lymphatic detour, microtumor emboli in the lymphatics can then become “drop” metastasis, as often seen in patients with melanoma. This explains the consistent association between extensive nodal disease at the mesenteric root and the occurrence of

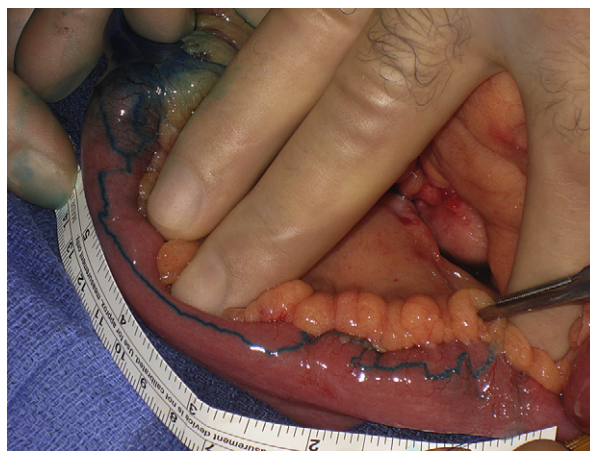

Fig 5. Longitudinal lymphatic drainage >18 cm proximal to the primary tumor.

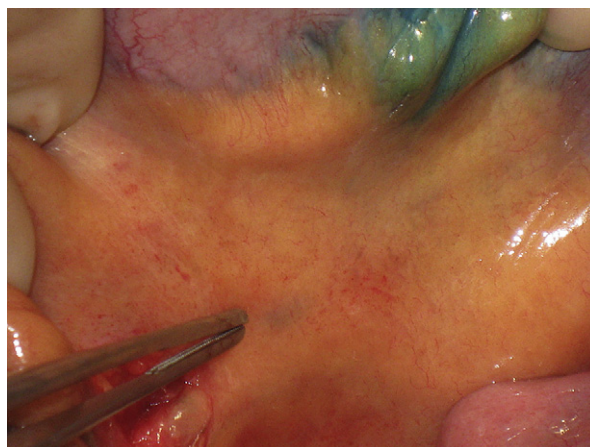

Fig 6. Normal radial drainage of midgut carcinoid.

multiple, often small, tumors along the length of the small bowel. It also may answer the question why recurrent carcinoid is always located at or near to the previous resection margin. Logically, the subserosal lymphatics, mapped out by the blue dye, might represent the true resection margin for midgut carcinoids. Another advantage of using lymphazurin blue lymphatic mapping is to delineate the limits of distal lymphatic drainage for terminal ileal carcinoids, allowing the operating team to determine whether the ileocecal valve can be preserved.

We have shown that this technique is safe, time effective, and well tolerated. Whether or not the implementation of lymphatic mapping for midgut carcinoid resection leads to a decrease in local recurrence, lesser incidence of postoperative diarrhea, fewer short gut symptoms, better quality of life, and eventually improvement in long-term survival will only become clearer with long-term

follow-up studies and a comparison of the long-term outcomes among the patients treated with and without mapping. The new developed radio-labeled methylene blue dye might be useful for mapping hindgut tumors or any carcinoid where the visualization of the lymphatic drainage might be insufficient to determine the resection margins.^{10,11} Detection of the radioactive signal may add to the utility of this technique in those cases.

REFERENCES

1. Modlin IM, Sandor A. An analysis of 8305 cases of carcinoid tumors. *Cancer* 1997;79:813-29.
2. Söreide JA, van Heerden JA, Thompson GB, Schleck C, Ilstrup DM, Churchward M. Gastrointestinal carcinoid tumors: long-term prognosis for surgically treated patients. *World J Surg* 2000;24:1431-6.
3. Hellman P, Lundström T, Ohrvall U, Eriksson B, Skogseid B, Oberg K, et al. Effect of surgery on the outcome of midgut carcinoid disease with lymph node and liver metastases. *World J Surg* 2002;26:991-7.
4. Sutton R, Doran HE, Williams EM, Vora J, Vinjamuri S, Evans J, et al. Surgery for midgut carcinoid. *Endocr Relat Cancer* 2003;10:469-81.
5. Krag D, Weaver D, Ashikaga T, Moffat F, Klimberg VS, Shriver C, et al. The sentinel node in breast cancer: a multicenter validation study. *N Engl J Med* 1998;339:941-6.
6. Krag DN, Harlow S, Weaver D, Askikaga T. Radiolabeled sentinel node biopsy: a collaborative trial with the National Cancer Institute. *World J Surg* 2001;25:823-8.
7. Kelley MC, Hansen N, McMasters KM. Lymphatic mapping and sentinel lymphadenectomy for breast cancer. *Am J Surg* 2004;188:49-61.
8. Cahill RA. What's wrong with sentinel node mapping in colon cancer. *World J Gastroenterol* 2007;13:6291-4.
9. Bell SW, Mourra N, Flejou JF, Parc R, Tiret E. Ex vivo sentinel lymph node mapping in colorectal cancer. *Dis Colon Rectum* 2005;48:74-9.
10. Stafford SJ, Wright JL, Schwimer J, Anthony CT, Cundiff JD, Thomson JL, et al. Development of ¹²⁵I-methylene blue for sentinel node lymph biopsy. *J Surg Onc* 2006;94:293-7.
11. Cundiff JD, Wang YZ, Espenan G, Maloney T, Camp A, Lazarus L, et al. A phase I/II trial of ¹²⁵I methylene blue for one-stage sentinel lymph node biopsy. *Ann Surg* 2007;245:290-6.

DISCUSSION

Dr Janice L. Pasiaka (Calgary, Alberta, Canada): Thank you very much for bringing a novel technique to us. I think, as you alluded to, these are very challenging patients and the more aggressive we can be surgically the better these patients will do. My question is on a technical aspect. When you have the multiple tumors, which tumor do you inject to do the lymphatic mapping? How do you decide which tumor to inject?

Dr Yi-Zarn Wang (New Orleans, LA): When we have a patient with multiple tumors, we try to define which most likely represents the primary tumor. We inject the

blue dye around that one. In cases with multiple tumors, we inject the most proximal one and the most distal one to ensure that we have the widest drainage pattern possible.

Dr Scott Wilhelm (Cleveland, OH): I have 2 questions for you. One, what was the primary presentation in most of your patients who had the midgut carcinoids? Did these people present with small bowel obstructions or were these incidental findings in patients with abdominal pain? Did these patients have pain, get a computed tomography (CT) scan and the mesenteric mass was an incidental finding? Second, you alluded to the fact that you are hoping that this technique may decrease chances for local recurrence. Do you have any follow-up on any of these patients that you have done so far, even if it's early, in terms of any recurrence data or not?

Dr Yi-Zarn Wang (New Orleans, LA): Let me answer the second question first. We don't have any long-term follow-up yet; but hopefully, I will be able to show you what we have found in a year or 2. In terms of the patient population, we have become a referral center and thus most of the patients are diagnosed somewhere else and sent to us. Most commonly these patients present with abdominal pain and are found to have a mesenteric mass during their radiologic workup.

Dr Richard A. Hodin (Boston, MA): Can you give us some insight into how often this lymphatic mapping may have made you excise more versus less bowel? Theoretically it could work in either direction.

Dr Yi-Zarn Wang (New Orleans, LA): In general, this technique leads to resection of slightly more bowel. Usually when you do the small bowel resection you choose your resection margins based on gross examination of the specimen. With the lymphatic mapping technique guiding the resection, most of the time the traditional margin was inadequate.

Dr Richard A. Hodin (Boston, MA): In your discussion, were you referring to taking out lymph nodes and leaving the blood vessels in cases where there was mesenteric encasement?

Dr Yi-Zarn Wang (New Orleans, LA): Yes. We spend a lot of time carefully dissecting the node from the vessels. When we finish, hopefully we leave the vessels with no surrounding tissue.

Dr Emus Camden (New Orleans, LA): I'm interested in your experience with the frozen sections of your margins. Do you need to check these margins with frozen sections?

Dr Yi-Zarn Wang (New Orleans, LA): We hardly ever use a frozen section to determine the adequacy of our margins. We tried it a couple times in the past, because we were worried about these margins. All of these were negative so we stopped doing frozen sections and on review we have had no positive permanent bowel resection margins.