

# The NANETS Consensus Guideline for the Diagnosis and Management of Neuroendocrine Tumors

## *Well-Differentiated Neuroendocrine Tumors of the Jejunum, Ileum, Appendix, and Cecum*

*J. Philip Boudreaux, MD,\* David S. Klimstra, MD,† Manal M. Hassan, MD, PhD,‡ Eugene A. Woltering, MD,\* Robert T. Jensen, MD,§ Stanley J. Goldsmith, MD,|| Charles Nutting, DO,¶ David L. Bushnell, MD,# Martyn E. Caplin, MD,\*\* and James C. Yao, MD‡*

**Abstract:** Well-differentiated neuroendocrine tumors (NETs) of the jejunum, ileum, and appendix are also collectively known as midgut carcinoids. Similar to NETs in general, the diagnosed incidence of the midgut NETs is on the rise. Their presenting symptoms vary depending on stage and primary site. Local-regional NETs often present with vague and nonspecific symptoms. Classic carcinoid syndrome is more likely to appear in patients with advanced disease. Local-regional NETs of the small bowel should be resected whenever possible. With the exception of small well-differentiated NETs of the appendix, NETs of the midgut have substantial risk of relapse after resection and need to be followed for at least 7 years.

Metastatic/advanced NETs of the midgut are incurable. Optimal management requires a multidisciplinary approach. Somatostatin analogs are effective in the management of carcinoid syndrome. Octreotide long-acting release has also recently been shown to delay disease progression. Liver-directed therapy and surgical debulking can improve quality of life in selected patients. Pivotal phase 3 studies with bevacizumab targeting vascular endothelial growth factor and everolimus targeting mTOR (mammalian target of rapamycin) are ongoing and may lead to improved outcome. Further studies of novel approaches such as peptide receptor radiotherapy are also warranted.

**Key Words:** neuroendocrine tumors, jejunum, ileum, appendix, cecum (*Pancreas* 2010;39: 753–766)

**A**lthough NETs at any site can produce hormone(s), well-differentiated NETs of the jejunum, ileum, appendix, and cecum are most closely associated with the classic carcinoid syndrome and are often described as midgut carcinoids because of their common embryologic origin.

From the \*Department of Surgery, Louisiana State University Health Sciences Center, New Orleans, LA; †Department of Pathology, Memorial Sloan-Kettering Cancer Center, New York, NY; ‡Department of Gastrointestinal Medical Oncology, University of Texas M. D. Anderson Cancer Center, Houston, TX; §Digestive Diseases Branch, National Institutes of Health, Bethesda, MD; ||Division of Nuclear Medicine, Department of Radiology, New York-Presbyterian Hospital, Weill Medical College of Cornell University, New York, NY; ¶Department of Interventional Radiology, Swedish Medical Center, Englewood, CO; #Department of Radiology, University of Iowa Hospitals and Clinics, Iowa City, IA; and \*\*Centre for Gastroenterology, Royal Free Hospital, London, UK.

Reprints: James C. Yao, MD, Department of Gastrointestinal Medical Oncology, Unit 426, University of Texas M. D. Anderson Cancer Center, 1515 Holcombe Blvd, Houston, TX 77030 (e-mail: jyao@mdanderson.org).

Copyright © 2010 by Lippincott Williams & Wilkins

Symptoms for patients with early disease are often vague and insidious in onset, leading to long delays in diagnosis. Early in the disease process, patients can have nonspecific abdominal symptoms such as cramping, bloating, and mild episodic diarrhea. Often patients are mislabeled as having irritable bowel disease. It has been speculated that these symptoms may be due to local effect of serotonin or mechanical effect of primary tumor. Generally, serotonin secreted from local-regional NETs does not reach systemic circulation as they are inactivated by the liver as they pass through the portal circulation. More severe symptoms due to local-regional disease can occur secondary to acute obstruction from primary tumor or mesenteric fibrosis or ischemia secondary to mesenteric vascular involvement. The presence of an occult NET should be considered for patients with chronic bowel complaints or postprandial pain suggestive of ischemia. Flushing and diarrhea are mostly likely to be present in the setting of metastases. Other signs and symptoms leading to the diagnosis of advanced NETs include hepatomegaly and right-upper-quadrant pain.

Optimal management requires a multidisciplinary approach. Because of the limited amount of definitive data from random-assignment studies, much of the management decisions are based on experience and expert recommendations. The North American Neuroendocrine Society convened a panel of leading clinicians and investigators from the United States, Canada, and Europe to recommend management options for NETs. The current article describes consensus recommendations for the midgut NETs.

### EPIDEMIOLOGY

The age-adjusted diagnosed incidence rate of malignant NETs arising from jejunum and ileum in the Surveillance, Epidemiology, and End Results (SEER) Program database is 0.67 per 100,000 per year.<sup>1</sup> Annual incidence rates for NETs of the appendix and cecum are 0.16 and 0.15 per 100,000, respectively.<sup>1</sup> Time-trend analyses have shown a rise in the diagnosed incidence of NETs including those of the jejunum, ileum, appendix, and cecum. The true incidence rates of NETs at these sites are likely to be substantially higher for several reasons. First, NETs of the small bowel are difficult to diagnose and likely account for a substantial number of unknown primary NETs. Second, data obtained from the SEER registries likely underestimated the total number of patients with NETs. Only patients with malignant NETs are included in the SEER registries. Whereas histological criteria of malignancy have long been well defined for most epithelial neoplasms, the definition of malignancy in NETs has been more controversial. In the absence of

obvious malignant behavior, such as direct invasion of adjacent organs or metastasis to regional lymph nodes or distant sites, some NETs have been regarded as “benign.” Thus, data on many small, localized NETs (ie, typical appendiceal carcinoid tumors) likely have been excluded from the registries that contain only malignant neoplasms, such as SEER. Finally, data from 2 large autopsy series suggest the incidence of NETs of small bowel to be substantially higher at 0.7% to 1.2% of unselected autopsy cases.<sup>2,3</sup>

The incidence rates of appendiceal and cecal NETs were similar between male and female. However, for jejunal and ileal NETs, the incidence rate was slightly higher among males (0.8 vs 0.57/100,000).<sup>1</sup> The differences in incidence rates by race are more striking.<sup>1</sup> For NETs of the jejunum and ileum, the incidence rates among white, African Americans, and Asian/Pacific Islander patient groups were 0.71, 0.88, and 0.09 per 100,000, respectively. Similarly, for NETs of the cecum, the incidence rates among white, African Americans, and Asian/Pacific Islander patient groups were 0.17, 0.21, and 0.04 per 100,000. Finally, for NETs of the appendix, the incidence rates among white, African Americans, and Asian/Pacific Islander patient groups were 0.16, 0.14, and 0.03 per 100,000.

The median age at diagnosis for midgut NETs was 64 (SD, 15.5) years in the SEER registry.<sup>4</sup> Patients in appendiceal subgroup were younger at diagnosis, with a median age of 47 (SD, 18) years. However, the true age at diagnosis for appendiceal NETs is likely even lower because most small tumors found incidentally at appendectomy are considered benign and not reported to SEER. Those with jejunal/ileal and cecal NETs had similar age at diagnosis (66 [SD, 13] and 68 [SD, 14] years, respectively). Stage distribution at diagnosis from the SEER program database for G1/G2 midgut NETs by primary site is provided in Table 1.

Population studies suggested that patients with small-bowel carcinoid tend have positive family history of several cancers. Significant increase in the risk of small-bowel carcinoid development was observed in relation to the presence of a family history of prostate cancer or colorectal cancer among patients’ first-degree relatives.<sup>5</sup> Moreover, the risk of small-bowel carcinoid was elevated among those whose siblings were affected by tongue or mouth cancer.<sup>6</sup> Relative risk and 95% confidence interval (CI) was 3.99 (range, 1.28–12.5). In addition, parental cancers of the endometrium, kidney, skin, and non-Hodgkin lymphoma were associated with small-bowel carcinoid in the offspring. Meanwhile, very little is known about environmental risk factors of this tumor. Cigarette smoking and alcohol consumption are not significantly associated with disease development.<sup>7–10</sup> However, assessment for the potential impact of nutritional factors indicated a significant association between high intake of saturated fat and carcinoid of the small intestine. The estimated hazard ratio (HR) and 95% CI were 3.7 (range,

**TABLE 1.** Stage Distribution at Time of Diagnosis Based on SEER Program Database (1973–2004)

Primary Site	Stage		
	Localized	Regional	Distant
Jejunum/ileum	29%	41%	30%
Cecum	14%	42%	44%
Appendix	60%	28%	12%

Adapted from Journal of Clinical Oncology.<sup>1</sup>

**TABLE 2.** Minimum Pathology Dataset: Information to be Included in Pathology Reports on NETs of the Midgut

**For Resection of Primary Tumors**

- Anatomical site of tumor
- Diagnosis (functional status need not be included in pathology report)
- Size (in 3 dimensions)
- Presence of unusual histological features (oncocytic, clear cell, gland forming, etc)
- Presence of multicentric disease
- (Optional: immunohistochemical staining for general neuroendocrine markers)
  - Chromogranin
  - Synaptophysin
- Grade (specify grading system used)
- Mitotic rate (number of mitoses per 10 high-power fields or 2 mm<sup>2</sup>; count 50 high-power fields in the most active regions)
- (Optional: Ki-67 labeling index [count multiple regions with highest labeling density, report average percentage; “eyeballed” estimate is adequate])
- Presence of nonischemic tumor necrosis
- Presence of other pathological components (eg, nonneuroendocrine components)
- Extent of invasion
  - Depth of invasion into/through bowel or appendiceal wall
- Involvement of serosal/peritoneal surfaces
- Invasion of adjacent organs or structures
- Presence of vascular invasion (optional: perform immunohistochemical stains for endothelial markers if needed)
- Presence of perineural invasion
- Lymph node metastases
  - No. positive nodes
  - Total no. nodes examined
- TNM staging (specify staging system used)
- Resection margins (positive/negative/close) (optional: measure distance from margin if within 0.5 cm)

**For Biopsy of Primary Tumors**

- Anatomic site of tumor
- Diagnosis (functional status need not be included in pathology report)
- Presence of unusual histological features (oncocytic, clear cell, gland forming, etc)
- (Optional: immunohistochemical staining for general neuroendocrine markers)
  - Chromogranin
  - Synaptophysin
- Grade (specify grading system used)
- Mitotic rate (no. mitoses per 10 high-power fields or 2 mm<sup>2</sup>; count up to 50 high-power fields)
- Ki-67 labeling index, for biopsies in which a diagnosis of high-grade neuroendocrine carcinoma cannot be excluded (count multiple regions with highest labeling density, report average percentage; eyeballed estimate is adequate)
- Presence of nonischemic tumor necrosis
- Presence of other pathological components (eg, nonneuroendocrine components)

1.8–7.7) for each 10-g increase in intake per 1000 kcal.<sup>11</sup> On the other hand, intake of fiber from grains was associated with 40% reduction in risk of small-bowel carcinoid.<sup>12</sup>

**PATHOLOGY AND MOLECULAR GENETICS**

**Pathology**

A variety of proposals regarding the classification and nomenclature of neuroendocrine tumors (NETs) have appeared, and many of these differ somewhat regarding specific terminology and criteria for grading and staging. Most proposed systems have indeed proven useful to stratify prognostic subgroups of NETs. However, the differences in criteria have resulted in much confusion. It would be of great benefit if a single system of nomenclature, grading, and staging could be developed; however, some of the systems that have arisen independently are now firmly established or recognized by organizations charged with standardizing terminology, such as the World Health Organization (WHO). Also, compelling clinical data favoring one system over another do not exist. Thus, abandoning some of the current systems in favor of a single, uniform proposal has proven impractical. On the other hand, careful examination of the existing proposals reveals many common features that underlie the classification and form the basis for grading and staging. Features such as the proliferative rate of the tumor and the extent of local spread (assessed based on similar parameters used for nonneuroendocrine carcinomas of the same anatomical sites) are shared by most systems. Therefore, it is recommended that these basic data elements used to stratify NETs be specified and documented in pathology reports, in addition to the utilization of a specified system of nomenclature, grading, and staging. By doing this, we ensure that the fundamental data necessary for prognostic assessment and therapy determination are recorded, allowing retrospective comparison of the characteristics of NETs, irrespective of the specific classification system that may currently be in vogue. A “minimum pathology data set” of features to be included in pathology reports on NETs of the colorectum, based on a recent multidisciplinary consensus recommendation as well as the College of American Pathologists’ “tumor checklists” for NETs, is presented in Table 2.

**Nomenclature**

The terminology for NETs varies by anatomical site but is uniform for these tumors throughout the midgut. In general, NETs are sharply divided into well-differentiated and poorly differentiated categories. Well-differentiated NETs are also referred to as carcinoid tumors and include both low- and intermediate-grade groups. Poorly differentiated NETs are considered high grade by definition (“high-grade neuroendocrine carcinomas”) and include small cell carcinoma and large cell neuroendocrine carcinoma. Cell size and nuclear morphology are used to distinguish small cell carcinoma from large cell neuroendocrine carcinoma. Combined (mixed) forms with elements of both high-grade neuroendocrine carcinoma

**TABLE 4.** Grading Systems for Neuroendocrine Tumors of the Midgut

Grade	Criteria
Low grade (G1)	<2 Mitoses/10 high-power fields, and <3% Ki-67 index
Intermediate grade (G2)	2–20 Mitoses/10 high-power fields, or 3%–20% Ki-67 index
High grade (G3)	>20 Mitoses/10 high-power fields or >20% Ki-67 index

and nonneuroendocrine carcinoma (usually adenocarcinoma) are also well recognized. Table 3 compares the various synonyms that exist for these different categories of neuroendocrine neoplasms of the midgut. Although the criteria that define each category do not perfectly match between the various systems, there are several common themes. Each system recognizes 3 grades. In each, the low and intermediate grades are closely related, well differentiated, and distinguished largely by proliferative rate (or necrosis). Finally, each system generally recognizes that well-differentiated and poorly differentiated features are rarely encountered within the same tumor. It is important to recognize that the unqualified terms “neuroendocrine carcinoma” or “neuroendocrine tumor,” without reference to grade or differentiation, are inadequate for prognostication or therapy and are considered inappropriate in pathology reports.

**Grading**

Grading of midgut NETs relies extensively on the proliferative rate to separate low, intermediate, and high grades. The grading system recently proposed for all gastroenteropancreatic NETs by ENETS (European Neuroendocrine Tumour Society) and also now recommended by the WHO uses either mitotic rate (expressed as mitoses per 10 high-power microscopic fields or 2 mm<sup>2</sup>) or the Ki-67 labeling index. This grading system is shown in Table 4. Definitive clinical data do not yet exist to determine whether the proliferation cut points used to distinguish the 3 grades are optimal, but studies are under way to validate the prognostic utility of this grading system. It is recommended to specify the actual proliferative rate in the pathology report, in addition to designating a grade based on a system that is specifically referenced.

**Staging**

As recently as a few years ago, no formal TNM-based staging systems existed for NETs for any anatomical sites. Recently, TNM staging systems have been proposed. The American Joint Committee on Cancer (AJCC) and the ENETS have each

**TABLE 3.** Nomenclature for NETs of the Midgut

Grade	Traditional	ENETS, WHO	Moran et al
Low grade	Carcinoid tumor	Neuroendocrine tumor, grade 1 (G1)	Neuroendocrine carcinoma, grade 1
Intermediate grade	Carcinoid tumor*	Neuroendocrine tumor, grade 2 (G2)	Neuroendocrine carcinoma, grade 2
High grade	Small cell carcinoma	Neuroendocrine carcinoma, grade 3 (G3), small cell carcinoma	Neuroendocrine carcinoma, grade 3, small cell carcinoma
	Large cell neuroendocrine carcinoma	Neuroendocrine carcinoma grade 3 (G3), large cell neuroendocrine	Neuroendocrine carcinoma, grade 3, large cell neuroendocrine carcinoma

\*Criteria to define a category of “atypical carcinoid tumor” have never been developed for the intestines or appendix.

**TABLE 5.** AJCC and ENETs Staging for NETs

	AJCC	ENETs
<b>A. AJCC and ENETs staging for NETs of the small intestine</b>		
Primary tumor (T)		
TX	Primary tumor cannot be assessed	Primary tumor cannot be assessed
T0	No evidence of primary tumor	No evidence of primary tumor
T1	Tumor invades lamina propria or submucosa and size ≤1 cm	Tumor invades mucosa or submucosa and size ≤1 cm
T2	Tumor invades muscularis propria or size >1 cm	Tumor invades muscularis propria or size >1 cm
T3	Tumor invades through the muscularis propria into the subserosa or into the nonperitonealized tissue	Tumor invades subserosa
T4	Tumor invades the visceral peritoneum (serosa) or any other organs or structures	Tumor invades peritoneum/other organs
		<i>Note:</i> For any T add (m) for multiple tumors
Regional lymph nodes (N)		
NX	Regional lymph nodes cannot be assessed	Regional lymph nodes cannot be assessed
N0	No regional lymph node metastasis	No regional lymph node metastasis
N1	Regional lymph node metastasis	Regional lymph node metastasis
Distant metastasis (M)		
MX	—	Distant metastasis cannot be assessed
M0	No distant metastasis	No distant metastasis
M1	Distant metastasis	Distant metastasis

Stage	AJCC			Stage	ENETs		
	T	N	M		T	N	M
0	Tis	N0	M0	—	—	—	—
I	T1	N0	M0	I	T1	N0	M0
IIA	T2	N0	M0	IIA	T2	N0	M0
IIB	T3	N0	M0	IIB	T3	N0	M0
IIIA	T4	N0	M0	IIIA	T4	N0	M0
IIIB	Any T	N1	M0	IIIB	Any T	N1	M0
IV	Any T	Any N	M1	IV	Any T	Any N	M1

**B. AJCC and ENETs staging for NETs of the appendix**

Primary tumor (T)		
TX	Primary tumor cannot be assessed	Primary tumor cannot be assessed
T0	No evidence of primary tumor	No evidence of primary tumor
T1	Tumor ≤2 cm in greatest dimension	Tumor ≤1 cm invading submucosa and muscularis propria
T1a	Tumor 1 cm or less in greatest dimension	—
T1b	Tumor >1 cm but not >2 cm	—
T2	Tumor >2 cm but not >4 cm or with extensions to the cecum	Tumor ≤2 cm invading submucosa, muscularis propria and/or minimally (up to 3 mm) invading subserosa/mesoappendix
T3	Tumor more than 4 cm or with extension to the ileum	Tumor invades subserosa/pericolic/perirectal fat
T4	Tumor directly invades other adjacent organs or structures, eg, abdominal wall and skeletal muscle*	Tumor invades peritoneum/other organs
Regional lymph nodes (N)		
NX	Regional lymph nodes cannot be assessed	Regional lymph nodes cannot be assessed
N0	No regional lymph node metastasis	No regional lymph node metastasis
N1	Regional lymph node metastasis	Regional lymph node metastasis
Distant metastasis (M)		
MX	—	Distant metastasis cannot be assessed
M0	No distant metastasis	No distant metastasis

(Continued on next page)

TABLE 5. (Continued)

M1	AJCC			ENETs			
	Distant metastasis			Distant metastasis			
	AJCC			ENETs			
Stage	T	N	M	Stage	T	N	M
I	T1	N0	M0	I	T1	N0	M0
II	T2, T3	N0	M0	IIA	T2	N0	M0
				IIB	T3	N0	M0
III	T4	N0	M0	IIIA	T4	N0	M0
	Any T	N1	M0	IIIB	Any T	N1	M0
IV	Any T	Any N	M1	IV	Any T	Any N	M1

\*Tumor that is adherent to other organs or structures, grossly, is classified cT4. However, if no tumor is present in the adhesion, microscopically, the classification should be classified pT1-3 depending on the anatomical depth of wall invasion.

recently published TNM staging systems for NETs of the small bowel, large bowel, and appendix. There are some differences between these systems, which are displayed in Table 5. However, because data are yet to be collected to validate the parameters used for separating different stages, it is recommended that the extent of involvement of the structures in the bowel wall be specifically indicated in the pathology reports. This will allow easy conversion to any newer, data-based staging systems that may emerge. Reports should provide a TNM stage based on a system that is specifically referenced.

### Other Pathology Information

A variety of other pathological findings may be of use in the prognostication and management of patients with NETs (Table 2). Immunolabeling for general neuroendocrine markers (chromogranin A [CgA] and synaptophysin) may not be needed in histologically typical resected primary tumors, but these stains are very important in many biopsy specimens to confirm the nature of the tumor. Immunolabeling for specific peptide hormones is useful only in highly defined circumstances, however. Adverse prognostic factors not included in grading and staging, such as vascular or perineural invasion, should be documented. Adequacy of surgical resection should be indicated, and the number of involved lymph nodes (as well as the total number of nodes examined) should also be stated. A variety of prognostic or treatment-related biomarkers has been investigated, and some may have significant utility in the future, but currently, none is recommended to be used routinely, outside specific research settings.

### Mixed Differentiation in NETs of the Midgut

In addition to classic NETs, mixed histology tumors having neuroendocrine and glandular features can be observed, especially in the appendix. Nonneuroendocrine components are relatively common in poorly differentiated (high grade) neuroendocrine carcinomas throughout the gastrointestinal tract. But in the appendix, there exist a number of relatively unique well-differentiated NETs that exhibit glandular features. Tubular carcinoid tumors are closely related to classic carcinoid tumors, including the presence of uniform nuclei, a low proliferative rate, and diffuse immunorepression of neuroendocrine markers, but the neoplastic cells are arranged in simple tubular glands rather than solid nests. The prognosis of appendiceal tubular carcinoid tumors is the same as for classic carcinoid tumors. Goblet cell carcinoid tumors consist of

nests of cells that contain abundant cytoplasmic mucin. The nuclei are uniform, and the proliferative rate is low, but the immunorepression of neuroendocrine markers is usually limited to a subset of the neoplastic cells. Goblet cell carcinoid tumors have the potential for more aggressive behavior than stage-matched classic carcinoid tumors of the appendix, and many cases display transformation to frank adenocarcinoma, a phenomenon associated with a much more aggressive clinical course.<sup>13</sup> For this reason, the management of goblet cell carcinoid tumors parallels that of primary adenocarcinomas of the appendix.

### Molecular Genetics

The genetics of neuroendocrine tumorigenesis have yet to be fully elucidated. Although small familial clusters of midgut carcinoids have been described, there are no known genetic cancer syndromes associated with the development of midgut NETs. Tumors have clustered in several small families without multiple endocrine neoplasia type 1, and multiplicity of tumors is a feature in 1 quarter of isolated cases. Studies of sporadic multicentric midgut carcinoids suggest that the multiple tumors represent intramural metastases, rather than independent primary tumors.<sup>14</sup> Among sporadic midgut carcinoids, several studies examining the genetics of ileal carcinoid tumors using comparative genomic hybridization or microsatellite markers have shown frequent allelic deletion of chromosome 18. On an epigenetic level, midgut NETs have been found to have global hypomethylation.<sup>15</sup> There are few data about the genetic aspects in NETs of the appendix or cecum. Tumor multiplicity is much less frequent in the appendix and cecum than in the ileum.

### IMAGING OF MIDGUT NETS

Imaging studies for NETs are generally done for initial evaluation for the extent of disease and subsequent follow-up. Goals for initial evaluation include identification of primary tumor, staging, and treatment planning. Subsequent follow-up imaging studies are done for surveillance after complete resection or during periods of stability and evaluation of response after treatment. Imaging modality commonly used includes the following:

- small-bowel series,
- computed tomography (CT),
- magnetic resonance imaging (MRI),
- [<sup>111</sup>In-DTPA<sup>0</sup>]octreotide scintigraphy,
- metaiodobenzylguanidine (MIBG) scintigraphy, and
- positron emission tomography (PET).

## Initial Evaluation for the Extent of Disease in Midgut NETs

Imaging studies generally recommended at the time of initial evaluation include plain film radiography of the chest, cross-sectional imaging (CT or MRI) of the abdomen and pelvis, and [ $^{111}\text{In-DTPA}^0$ ]octreotide scintigraphy. In cases where a midgut primary is suspected but not directly identified (eg, a mesenteric mass in the ileal mesentery), often small-bowel series or multiphase CT of the abdomen and pelvis with thin section and negative bowel contrast can be used to locate the primary tumor.

## Follow-Up Imaging of NETs

Among patients undergoing surveillance after complete resection, we recommend chest radiograph and periodic (every 6–12 months) cross-sectional imaging of the abdomen and pelvis. The role of routine [ $^{111}\text{In-DTPA}^0$ ]octreotide scintigraphy has not been defined by prospective studies. Many experts, however, would advocate the use of [ $^{111}\text{In-DTPA}^0$ ]octreotide scintigraphy for yearly follow-up evaluation of patients without evidence of disease or on an as-needed basis to resolve difficult issues.

For patients with advanced disease, we generally recommend the use of cross-sectional imaging for known sites of disease. Chest radiograph can be used as a screening examination for patient without evidence of thoracic disease. [ $^{111}\text{In-DTPA}^0$ ]octreotide scintigraphy can be used to test *in vivo* for the presence of somatostatin receptors 2 and 5. It can also be used to evaluate if peptide receptor radiotherapy (PRRT) represents a good treatment option.

## Techniques for Cross-Sectional Imaging

Neuroendocrine tumors are generally vascular tumors that enhance intensely with intravenous contrast during early arterial phases of imaging with washout during the delayed portal venous phase. The key to detecting small NETs on CT is to maximize the contrast between the tumor and the adjacent normal parenchyma. For abdominal and pelvic imaging, we recommend multiphase CT that includes the arterial phase and the portal venous phase. Rapid intravenous bolus of intravenous contrast is also recommended. Thin sectioning and the use of a negative oral contrast agent also may be helpful in detecting small primary tumor in the small bowel that may not otherwise be seen (Fig. 1).

Magnetic resonance imaging is preferred over CT for patients with a history of allergy to iodine contrast material or for those with renal insufficiency. Neuroendocrine tumors can have variable appearances on noncontrast MRI. They can be hypointense or isointense on T1-weighted images. Metastases to the liver typically

are usually high signal on T2-weighted images.<sup>16</sup> Because T2-weighted images are obtained without intravenous contrast, they do not have the problems of variations in the timing of phases of contrast enhancement. T2-weighted imaging can be especially useful for patients unable to receive contrast. However, these metastases, especially when cystic or necrotic, can mimic the appearance of other T2 high-signal-intensity lesions, such as hemangiomas and, occasionally, cysts.<sup>17</sup> Dynamic contrast-enhanced imaging can provide additional information about the nature of the lesions and help to detect smaller lesions. We recommend T1-weighted, T2-weighted imaging, and multiphase (arterial, portal venous, and delayed) dynamic MRI for NETs.<sup>16,18</sup>

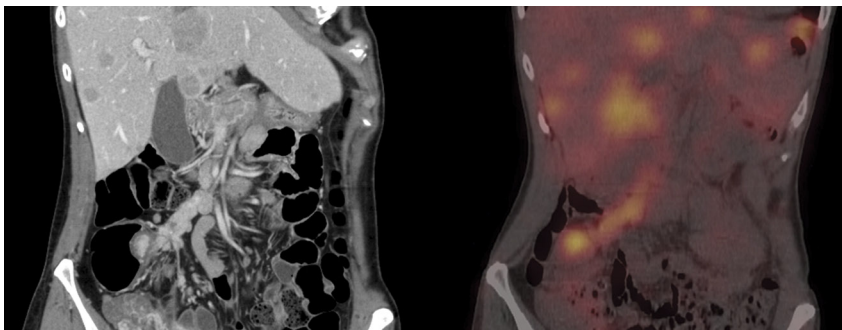
Some have reported that MRI may be more sensitive than CT for the detection of small liver metastases.<sup>19,20</sup> However, the CT may be better for the evaluation of peritoneal and mesenteric disease. It is likely that whether CT or MRI is better overall for NETs will continue to be debated and may vary depending on the expertise of the local center.

## Nuclear Imaging of NETs

$^{111}\text{In}$ -labeled somatostatin analog [ $^{111}\text{In-DTPA}^0$ ]octreotide was developed for scintigraphy of NETs. It shares the receptor-binding profile of octreotide, which makes it a good radiopharmaceutical for imaging of somatostatin receptors 2 and 5-positive tumors.<sup>21</sup> The overall sensitivity of [ $^{111}\text{In-DTPA}^0$ ]octreotide scintigraphy appears to be about 80% to 90%.<sup>21</sup> Unlike cross-sectional imaging, which is generally site directed, [ $^{111}\text{In-DTPA}^0$ ]octreotide scintigraphy is done as whole-body imaging and thus can detect disease at unsuspected sites.

Imaging is generally performed at 4 to 6 hours and at 24 hours.<sup>22</sup> Imaging at 24 hours provides better contrast because of lower background activity. However, there is often physiological bowel activity that may produce false-positive results. At 4 to 6 hours, some lesions may be obscured by relatively high background activity; however, bowel activity is limited. In some cases, additional imaging at 48 hours may be needed when there is significant bowel activity at the 24-hour scan, which may potentially obscure lesions that provide additional information. Single photon emission CT imaging with CT fusion (coregistration; Fig. 1) may be helpful in resolving the nature of indeterminate lesions found on CT and enhance the sensitivity and specificity of the study.

[ $^{111}\text{In-DTPA}^0$ ]octreotide scintigraphy can be performed for patients on long-acting octreotide but is best performed at end of the dosing interval (3–6 weeks after the last dose). For patients on octreotide delivered via a continuous infusional pump or those who received intermittent short-acting octreotide for rescue, we



**FIGURE 1.** Cross-sectional and nuclear imaging in midgut NETs. Left, Multiphase thin-section CT with negative oral contrast demonstrates primary ileal NETs with regional nodal disease and liver metastases. Right, [ $^{111}\text{In-DTPA}^0$ ]octreotide scintigraphy with CT fusion demonstrating somatostatin receptors 2 and/or 5 bearing tumor in the same patient.

would recommend that these be stopped for 48 hours before and during testing if possible. Although [ $^{111}\text{In-DTPA}^0$ ]octreotide scintigraphy can provide useful information about the site of disease, it does not give information about size. Some agents such as interferon (IFN) may upregulate somatostatin receptors and thus can lead to increased uptake without disease progression. [ $^{111}\text{In-DTPA}^0$ ]octreotide scintigraphy is also sometimes performed to evaluate the feasibility of PRRT as a scan with intense uptake at all known sites of disease is associated with a higher response rate after radiotherapy with somatostatin receptor targeting.

$^{123}\text{I-MIBG}$  molecular imaging has also been used for NETs but have the greatest efficacy in patients with pheochromocytoma, paraganglioma, or neuroblastoma. [ $^{111}\text{In-DTPA}^0$ ]octreotide generally has a higher sensitivity than  $^{123}\text{I-MIBG}$  for midgut NETs. Nonetheless, some tumors, negative on [ $^{111}\text{In-DTPA}^0$ ]octreotide scintigraphy, can be better seen with  $^{123}\text{I-MIBG}$ .

Positron emission tomography [ $^{18}\text{F}$ ]-fluorodeoxyglucose (FDG) imaging, although successful for many solid tumors, has generally not provided additional information about the extent of disease for well-differentiated NETs because of their generally lower proliferative activity. Although most NETs are imaged by FDG, FDG uptake in more undifferentiated and nonsecretory tumors tends to be more prominent. Fluorodeoxyglucose PET should be used for poorly differentiated and undifferentiated tumors or when [ $^{111}\text{In-DTPA}^0$ ]octreotide or  $^{123}\text{I-MIBG}$  are negative or equivocal. [ $^{18}\text{F}$ ]-fluorodeoxyglucose PET imaging may also be used to characterize tumor aggressiveness with higher FDG uptake (expressed as SUV values) having a worse prognosis. This may be helpful when the tumor seems more aggressive than the histology indicates and additional information for FDG imaging may result in changes of treatment.

Prior studies have shown  $^{11}\text{C}$ -5-hydroxytryptophan (HTP) PET to be a promising imaging modality for the detection of NETs.<sup>23</sup> The serotonin precursor 5-HTP labeled with  $^{11}\text{C}$  was used and showed an increased uptake and irreversible trapping of this tracer in NETs.<sup>23</sup> [ $^{11}\text{C}$ ]-5-HTP PET proved better than somatostatin receptor scintigraphy for tumor visualization. However, the short half-life of  $^{11}\text{C}$  ( $t_{1/2} = 20$  minutes) makes it difficult to apply in clinical practice. Other new PET imaging agents for NETs include  $^{18}\text{F}$ -FDOPA,  $^{68}\text{Ga}$ -DOTA-TOC,  $^{68}\text{Ga}$ -DOTA-NOC, and  $^{18}\text{F}$ -FPGluc-TOCA. In addition,  $^{99\text{m}}\text{Tc}$ -depreotide, which has a greater affinity to somatostatin receptor 3, has also been used for tumor imaging. Although these novel imaging techniques are promising, clinical experiences are limited. These techniques are generally not available in the United States.

### BLOOD AND URINE BIOMARKERS IN MIDGUT NETS

Several circulating tumor markers have been evaluated for the diagnosis and follow-up management of NETs. Although these can be very useful for follow-up, isolated elevation of marker levels is generally not sufficient for diagnosis without tissue confirmation. The most important of these markers, CgA, is a 49-kd acidic polypeptide that is widely present in the secretory granules of neuroendocrine cells. Depending on extent of disease, plasma CgA is elevated in 60% to 100% of patients with either functioning or nonfunctioning NETs. The sensitivities and specificities of CgA for the detection of NETs range between 70% and 100%.<sup>24-27</sup> Chromogranin A level may correlate with tumor volume, but care should be taken in measuring CgA and interpreting the results. For example, because somatostatin analogs are known to affect blood levels of CgA, serial CgA levels should be measured at approximately the same interval from injection in patients receiving long-acting somatostatin analogs. Spuriously elevated levels of CgA have

also been reported in patients using proton pump inhibitors, in patients with renal or liver failure, and in those with chronic gastritis. When used to monitor for recurrence after complete resection, patients should avoid proton pump inhibitors for 2 weeks, if possible, before CgA measurements.

Urinary 5-HIAA (24-hour collection) is a useful laboratory marker for carcinoid tumors. It is a surrogate measure of serotonin metabolism that is tightly linked to the presence of carcinoid syndrome. It is also perhaps more useful than the direct measurement of serotonin, as serum serotonin varies considerably during the day according to activity and stress level. The specificity of this test has been reported to be 88%.<sup>28</sup> However, certain foods and medications (Table 6) can increase urinary 5-HIAA levels and should be avoided during specimen collection.<sup>29</sup>

Another useful blood marker, neuron-specific enolase, is a dimer of the glycolytic enzyme enolase. Neuron-specific enolase is present in the cytoplasmic compartment of the cell, and its serum level is thought to be unrelated to the secretory activity of the tumor.<sup>27</sup> Although it is less specific than CgA, it can be a useful marker for follow-up of patients with a known diagnosis of NETs.

A variety of other secreted amines can be measured among patients with midgut NETs. These include other chromogranins such as chromogranins B and C, pancreastatin, substance P, neurotensin, neurokinin A, and fasting pancreatic polypeptide. In general, blood markers should be drawn in fasting state. Among patient on somatostatin analogs, they should be drawn at a consistent time point relative to timing for the administration of long-acting analogs.

It is recognized that NETs sometimes can change what (if any) hormones and biomarkers are produced. The general principle of biomarker measurement is to evaluate a large panel of marker at key points of the disease such as diagnosis or relapse to identify a few biomarkers that are elevated in a particular patient in question and follow these over time. It is generally not necessary to check every biomarker at every visit.

### MANAGEMENT OF LOCAL-REGIONAL DISEASE

Surgery remains the standard and only potentially curative therapy for patients with well-differentiated NETs of the midgut. However, outcome after surgery varies considerably among the

**TABLE 6.** Foods and Medications to Be Avoided During 5-HIAA Collection

Foods and Beverages	Medications
Alcoholic beverages	Phenacetin
Banana	Cough and cold remedies containing expectorants
Black walnuts	Muscle relaxants: methocarbamol
Butternuts	Phenothiazines
English walnuts	Chlorpromazine
Kiwi	Prochlorperazine,
Mockernut	Promethazine, etc
Nuts	Methanamines
Pecans	
Pineapple	
Plantain	
Plums	
Shagbark	
Tomatoes	

midgut tumors. The 5-year survival rates for localized (node negative) well-differentiated NETs of the jejunum/ileum, cecum, and appendix were 65%, 68%, and 88%, respectively (Fig. 2).<sup>1</sup> Those of patients with regional disease from these same sites were 71%, 71%, and 78% (Fig. 2).<sup>1</sup>

### Surgical Approaches for Well-Differentiated NETs of the Midgut

#### NETs of the Appendix

Most appendiceal carcinoids are found retrospectively after operation for suspected acute appendicitis, and the majority of those are located at the tip of the appendix. Approximately 10% of patients will be found to have the base of the appendix involved with tumor. Small ( $\leq 1$  cm) well-differentiated carcinoids confined to the tip of the appendix that are completely excised can be regarded as cured if there is no evidence of lymphovascular invasion or invasion into the mesoappendix. Careful pathological examination of the specimen is required. There are other factors, however, that make appendiceal carcinoids worrisome. In a large retrospective review, 18% of appendiceal carcinoids were associated gastrointestinal malignancies. Whereas small appendiceal carcinoids are often considered benign, deep invasion or regional metastases have been reported among tumor between 1 and 2 cm. For patients with tumors 2 cm or greater, the 5-year mortality from appendiceal carcinoid was 29.5%. For 1-cm appendiceal tumors, there is a reported 5% mortality rate at 5 years. At present, we are recommending formal right hemicolectomy in patients found to have appendiceal carcinoids with evidence of tumor invasion at the base of the appendix, in patients with tumors greater than 2 cm, in those with tumor where size cannot be determined, those with incompletely resected tumors, in those with evidence of lymphovascular invasion, those with invasion of the mesoappendix, in patients with intermediate- to high-grade tumors, and in patients with mixed histology (goblet cell carcinoid, adenocarcinoid). Patients with obvious mesenteric nodal involvement should undergo a right hemicolectomy even if it means a return trip to the operating room. A rare tumor variant is the appendiceal adenocarcinoid (goblet cell carcinoid); these lesions should be treated like adenocarcinoma rather than a carcinoid tumor. Their behavior

is often like that of an aggressive adenocarcinoma with a high propensity to metastasize.

#### NETs of the Cecum

Cecal carcinoids are a small subgroup of NETs that are frequently metastatic at the time of diagnosis. They often present as silent large bulky lesions, presenting with gastrointestinal hemorrhage or obstruction. Their biologic behavior is generally more aggressive than appendiceal carcinoid. Surgical excision along standard oncological principles applies, with attention to adequate resection of mesenteric lymph node-bearing tissue. When small lesions are encountered, careful pathological examination is required. Other associated gastrointestinal malignancies are also common.<sup>30</sup>

#### NETs of the Jejunum and Ileum

Carcinoid tumor of the jejunum and ileum are generally thought to have greater malignant potential than appendiceal carcinoid. Even small lesions may be associated with regional or distant metastases. Patients are often diagnosed at the time of an operation undertaken for some other reason. The discovery of these tumors often occurs as a result of surgical exploration for chronic blood loss, intestinal obstruction, or in the course of evaluation of metastatic disease. Regardless of how they are found, the discovery of a primary gut-based NET should engender a diligent search for additional tumors by inspection and palpation. This often requires conversion of laparoscopic procedures to open procedures because these tumors are often small and multiple. In our experience, as many as 70 tumors have been found along a segment of bowel. Tumors larger than 1.5 cm in diameter are usually associated with metastasis at the time of discovery. Resection should proceed along oncological principles, even in the face of metastatic disease, if it is technically feasible. With modern therapies, patients with intestinal NETs may live long enough to develop mesenteric vascular ischemia or recurrent obstruction from lymph node metastases that are left behind in the mesentery. Resection of terminal ileal lesions often results in the loss of the ileocecal valve. We recommend making a concerted effort to preserve bowel length and the ileocecal

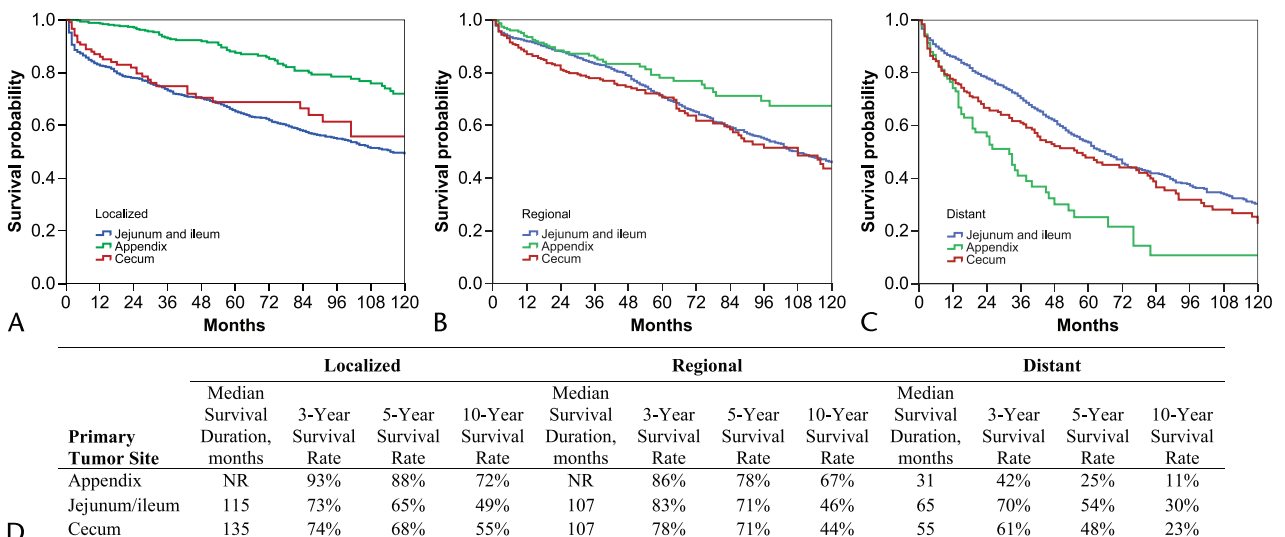


FIGURE 2. Overall survival among patients with midgut NETs. Survival by stage and primary site in patients with G1/G2 NETs diagnosed from 1988 to 2004. Cases were selected from SEER database (1973–2004) using International Classification of Diseases for Oncology third edition histology codes 8150–8157, 8240–8246, and 8249. Localized disease (A), regional disease (B), distant disease (C), survival by disease stage and primary tumor site (D).

valve, especially in patients with the carcinoid syndrome. Because diarrhea often accompanies the loss of the ileocecal valve, the coexistence of carcinoid syndrome increases the postoperative morbidity of this group of patients already at risk for debilitating diarrhea and malnutrition. We often use lymphatic mapping with isosulfan blue (Lymphazurin) or methylene blue dye to assess the lymphatic drainage pattern of the intestinal tumor. If longitudinally draining intramural intestinal lymphatics cross the ileocecal valve after injection of the peritumoral region with blue dye, we assume that the terminal ileocecal valve-cecal complex is at risk for lymphatic-born metastases. This is most likely to be the case in the presence of tumors 1 cm or larger and in patient with large nodal metastases in the mesentery. Conversely, if the intramural intestinal lymphatics abruptly turn towards the base of the mesentery before reaching the ileocecal valve, we feel confident trying to spare the valve.

Cholecystectomy at the time of exploration for local, regional, or distant metastatic disease is recommended because the majority of these patients will be on lifelong cholestasis-inducing somatostatin analogs.<sup>31</sup>

### Surgical Approach to Mesenteric Vascular Encasement

These tumors can also sometimes be associated with bulky mesenteric nodes that can cause obstruction, ischemia, or fibrosis causing mesenteric retraction. Surgical management of nodes involving the root of mesentery presents a special challenge that frequently causes vascular encasement. It is an insidious obliterative process with considerable variation in degree and rate of progression of desmoplasia, retraction, vascular ischemia, and intestinal obstruction. Symptoms of partial intestinal obstruction and/or mesenteric ischemia are often mixed and difficult to separate from the gastrointestinal symptoms of the carcinoid syndrome. The technique of mesenteric vascular dissection and decompression, although established, is difficult and tedious. We recommend patients to be evaluated by an experienced multidisciplinary team before deeming them nonoperative, unresectable candidates. Every effort to preserve bowel length should be undertaken, performing intestinal resection after the vascular dissection. Nearly 80% of patients explored elsewhere were successfully debulked in experienced centers familiar with the technique of resection of mesenteric metastases, with improvements in symptoms and survival. We also recommend that patients be reevaluated periodically by surgeons in concert with their oncologist to assess preoperative optimization, timing, and extent of resection.

As many as 35% of patients with advanced carcinoid present with symptoms of obstruction, ischemia, or both. In the emergent previously undiagnosed situation, resection of this immediate problem (ischemic, obstructed bowel) is accepted therapy. The bulky mesenteric or hepatic disease can be addressed once nutritional rescue is completed.

### Perioperative Management

Syndromic patients with metastatic midgut tumors present can be particularly challenging in the perioperative setting because of risk for carcinoid crisis from even minor procedures.<sup>32</sup> The degree of risk and severity of a crisis is difficult to predict, but patients with continuous flushing from poorly controlled syndrome are at especially increased risk.<sup>33</sup> The risk is also increased with manipulation of large, bulky serotonin-producing tumors, such as during liver resection or transplantation. Carcinoid crisis may manifest as hypotension or hypertension, flushing, tachycardia or bradycardia, bronchospasm, and complete vasomotor collapse. Treatment is best centered around prevention. Every

attempt at controlling the syndrome preoperatively should be undertaken. General preoperative preparation should also include correction of nutritional and electrolyte deficiencies.

Premedication with octreotide, such as a single subcutaneous injection of 250 to 500  $\mu\text{g}$ , should be sufficient prevention for most minor procedures.<sup>34</sup> We recommend having extra doses available in the operating room or treatment area, given in 250- $\mu\text{g}$  amounts or greater, should the need arise. For major procedures, a preoperative bolus of 250 to 500  $\mu\text{g}$ , followed by a continuous infusion of 50 to 500  $\mu\text{g/hr}$  during the procedure, has been reported.<sup>32,35,36</sup> The infusion is then weaned by 50% daily over a few days until it can be safely discontinued. Additional preoperative preparation can include short-acting corticosteroids, antihistamines ( $\text{H}_1$ - and  $\text{H}_2$ -blocking agents).<sup>37</sup> However, octreotide used in combination with steroids or in diabetic patients may complicate glucose management.<sup>35</sup>

Intraoperatively, hypotension not attributable to acute blood loss should be treated with boluses of octreotide, steroids, and volume expansion.<sup>32,35</sup> Bronchospasm can also be reversed in this manner.<sup>35</sup> Although vasopressors should be generally avoided because these agents are known to increase the release of serotonin and vasoactive amines from these tumors,<sup>32</sup> we and others have successfully used low doses of dopamine, vasopressin, and phenylephrine (Neosynephrine) in these patients once they are pretreated with octreotide as continuous infusion, without precipitation of carcinoid crises.<sup>32</sup>

### Adjuvant Therapy

At this time, there are insufficient data to recommend the use of adjuvant therapy after complete resection of local-regional disease.

### Follow-Up and Surveillance

Low-grade well-differentiated appendiceal carcinoids that are less than 1 cm in size have a low risk of recurrence and generally need not be followed. For appendiceal carcinoid 1 to 2 cm in size, we would recommend follow-up if other poor prognosis factors such as nodal metastasis, lymphovascular invasion, mesoappendiceal invasion, intermediate or high grade, or features of mixed histology (goblet cell carcinoid, adenocarcinoid) are identified. Most other midgut NETs carry a substantial risk for relapse. Although no prospective study has been attempted to demonstrate the utility of any specific follow-up regimen, it is generally accepted that post-resection surveillance can detect early relapse. This can lead to complete resection among some patients and early initiation of therapy in others.

Because of the indolent nature of the disease, patients need not be followed up at short intervals but for a longer period. We recommend that patients be reassessed once between 3 and 6 months after complete resection. Subsequently, patients should be assessed every 6 to 12 months for at least 7 years. Follow-up should consist of interval history, physical examination, CgA, and 5-HIAA, at minimum. Multiphasic CT or MRI is recommended by many experts. [<sup>111</sup>In-DTPA<sup>0</sup>]octreotide scintigraphy can be performed as clinically indicated.

### MANAGEMENT OF CARCINOID SYNDROME

The classic carcinoid syndrome consists of flushing and diarrhea. Wheezing, and in the case of carcinoid crisis, often caused by a severe and acute release of hormones, hemodynamic instability (hypertension or hypotension) and syncope can also occur. Patients with long-term uncontrolled carcinoid syndrome can also develop carcinoid heart disease and pellagra caused by niacin deficiency.

The commercial introduction of somatostatin analogs has led to vast improvements in the management of carcinoid syndrome. However, refractory flushing and diarrhea still occur. One should, however, remember that there can be multiple reasons for the exacerbation of symptoms in these patients. Imaging, biomarkers such as 5-HIAA, and careful history taking and physical examination can help select optimal therapeutic approaches.

The causes for refractory diarrhea in patients with midgut carcinoid include hormonal production by the tumor, short-gut syndrome after surgery, steatorrhea due to pancreatic exocrine insufficiency secondary to somatostatin analogs, and pellagra due to niacin deficiency. Serotonin-induced diarrhea in carcinoid syndrome is secretory in nature and occurs with or without food ingestion. Progressive elevation of urinary 5-HIAA or imaging studies showing disease progression would suggest increased hormonal production to be a significant component cause of the diarrhea. Escalating the dose of long-acting somatostatin analogs, shortening the interval between injections, or adding a short-acting agent is often the most effective solution. Other options may include adding nonspecific diarrheal agents, debulking the tumor, or adding IFN.

Patients with short-gut syndrome frequently will report the start or worsening of diarrhea after surgical resection of the small bowel or right colon. In some patients, this occurs after complete resection of the local-regional disease and leads to an extensive search for occult metastases in a patient without disease. Bile acid-binding agents such as cholestyramine or colestipol can often bring partial or complete relief.

Somatostatin analogs, especially given in high doses, can also cause a malabsorptive diarrhea. These patients often describe foul-smelling, floating, foaming, and greasy diarrhea after meals. These are often best managed by the addition of pancreatic enzymes (Creon, Ultrase) with meals.

Finally, patients with long-standing uncontrolled or poorly controlled carcinoid syndrome can develop niacin deficiency manifesting as pellagra, a syndrome consisting of diarrhea, dementia, and dermatitis. These patients can be best managed by supplementation with niacinamide or niacin.

### Somatostatin Analogs

The use of somatostatin congeners to block the release of bioactive peptides and amines is the mainstay for the control of the symptoms of carcinoid syndrome. In the United States, octreotide is the only somatostatin congener currently approved for the treatment of carcinoid syndrome. In Europe and in other parts of the world, lanreotide is also approved for the control of the flushing, diarrhea, and wheezing associated with the carcinoid syndrome. Octreotide acetate comes in 2 forms: an aqueous immediate-release product and a sustained-release (long-acting release [LAR]) form. The aqueous form is widely used initially in the long-term treatment plan as a test compound to determine safety and tolerability of the long-acting formulation. The aqueous form of octreotide is also commonly used, after the administration of LAR, as a subcutaneous rescue injection (100–500  $\mu\text{g}$  every 8–12 hours) for periods when the patient is exhibiting severe or recalcitrant symptoms. Currently, the LAR form of octreotide is offered in 10-, 20-, and 30-mg dosage forms, and the currently recommended starting dose is 20 mg/mo. Review of the octreotide drug registration data reveals that octreotide blood levels are weight dependent. Recent data suggest that up to 40% of patients who are treated with the LAR form of octreotide may need additional medication (rescue injections of aqueous octreotide) at some point during their therapeutic course.<sup>38</sup> The need for short-acting rescue medication for optimal symptom management is further supported by

the data from the registration study for octreotide LAR. In that trial, which randomized patients to 3 different doses of octreotide LAR or short-acting octreotide, 40% of the patients required weekly rescue medication, and 70% of patients required rescue injections at some time during the registration trial.<sup>39</sup> For patients with symptoms escaping control, dose escalation or increasing the frequency of long-acting injection can be considered. Because of long half-life of long-acting analogs, it may take up to 3 to 4 months for the drug to reach steady-state after initial treatment start or a change in dose.

Somatostatin analogs are generally well tolerated. Patients receiving the initial subcutaneous injection frequently experience a flushing episode lasting a few seconds. This usually does not return with subsequent injection of the long-acting material and should not be interpreted as an allergic reaction. Other adverse events can include gas, nonspecific gastrointestinal discomfort, and steatorrhea. A small number of patients on chronic octreotide may develop cholelithiasis, and approximately 1% may need cholecystectomy. Bradycardia (usually asymptomatic) can also be observed. For this reason, baseline electrocardiogram is recommended by some. Hyperglycemia and hypothyroidism have also been reported. Periodic (every 3–6 months) monitoring of glucose metabolism (fasting blood glucose or hemoglobin A<sub>1c</sub>) and yearly monitoring thyroid functions (thyroid-stimulating hormone, free T3, free T4) should be considered. Some experts also recommend the baseline and annual monitoring of vitamins B<sub>12</sub> and D.

### Interferon $\alpha$

The IFNs, IFN- $\alpha$ 2a and IFN- $\alpha$ 2b, bind to specific IFN receptors on NET cells. After binding of IFN to its receptor, a signal transduction cascade will be activated, leading to the transcription of multiple tumor suppressor genes. Interferon  $\alpha$  acts on specific enzymes (such as 2',5'-A-synthetase and p68 kinase), leading to the degradation of peptide hormones and inhibition of protein synthesis. In NETs, the indications for IFN are roughly similar (except carcinoid crisis) to those of somatostatin analogs.

Most investigations have studied recombinant IFN- $\alpha$ 2a or IFN- $\alpha$ 2b. In 30% to 70% of the patients with the carcinoid syndrome, symptomatic remission with IFN therapy is observed, with a superior effect on flushing as compared with diarrhea. The control of symptoms by IFN is similar to somatostatin analogs, but the onset of response is more delayed. In patients with the carcinoid syndrome, remission or stabilization of tumor markers and/or urinary 5-HIAA excretion was observed in 36% to 44% and 30% to 35%, respectively. In most patients, a flulike syndrome occurs in the first 5 days. Common adverse effects include anorexia, weight loss, fatigue, and dose-dependent bone marrow toxicity such as anemia, leukopenia, and thrombocytopenia. Less common adverse effects include hepatotoxicity, depression, mental disturbances, and visual impairment.<sup>40–52</sup> Endocrine disorders such as diabetes mellitus, and hypothyroidism have also been reported. Complete blood count and platelet counts should be evaluated at baseline for monitoring potential toxicity. These tests should be repeated 1 to 2 weeks after the initiation of therapy and monthly thereafter.

The combination of octreotide and IFN- $\alpha$  has also been studied. Patients for whom octreotide alone produced no benefit were included in 3 studies of 24, 19, and 9 patients. Patients for whom monotherapy with IFN- $\alpha$  had no benefit were also included in one of these studies.<sup>44</sup> Biochemical responses were reported in 77%, 72%, and 75% of the treated patients. These studies suggest that there may be synergism between somatostatin analogs and IFN in controlling carcinoid syndrome.

## Antidiarrheal Agents

Like in other causes of secretory diarrhea, opiates and loperamide have been used for symptomatic improvement of diarrhea in patients with the carcinoid syndrome.

## MANAGEMENT OF ADVANCED DISEASE

### Approach to the Management of Advanced Disease

Decision to initiate therapy is based on a number of clinical pathological factors including tumor grade, symptoms, performance status, and organ functions. Poorly differentiated NETs are more aggressive but more likely to respond to platinum-based chemotherapy. Because of the rapid rate of growth and spread, treatment should be initiated quickly (see The NANETS Consensus Guideline for the Diagnosis and Management of Neuroendocrine Tumors: Poorly Differentiated (High Grade) Extrapulmonary Neuroendocrine section). If tumor grade cannot be determined based on available tumor specimen, a second core needle biopsy should be strongly considered as the results may determine treatment options.

For well-differentiated NETs of the midgut, we recommend surgical resection if all diseases can be reasonably resected (R0). Cytoreductive resection should also be considered to alleviate symptoms or prevent complications. Initiation of therapy for control of tumor growth should be considered if patients have symptoms, bulky disease, or evidence of tumor growth. Treatment of asymptomatic patients with limited evaluable disease and no evidence of progression can also be considered using agents with favorable safety profile such as octreotide LAR. For patients with unresectable liver disease with tumors predominantly confined to the liver, liver-directed therapy should be considered.

Peptide receptor radiotherapy is not approved in the United States. For patients who can access such treatment, it presents an additional therapeutic option for those with significant uptake on [<sup>111</sup>In-DTPA<sup>0</sup>]octreotide scintigraphy.

### Systemic Therapy

Although substantial improvements in the management of carcinoid syndrome have been made, no new agent has been approved for the control of tumor growth over the last 3 decades. Despite having a reputation for being indolent, advanced midgut NET remains a deadly disease (Fig. 2). Several agents have been found to have a varying degree of activity in stabilizing tumor growth. Tumor regressions, however, are rare. Novel targeted agents such as vascular endothelial growth factor (VEGF) and mTOR (mammalian target of rapamycin) inhibitors have been found to be promising in NETs and are under development.

### Somatostatin Analogs

Somatostatin analogs have been widely used in NETs for the control of hormonal syndrome. Although somatostatin analogs have been also widely used for presumed cytostatic activity, until recently, there have been no prospective data to support the antiproliferative role of somatostatin analogs. In 2009, a multi-institutional German research group reported the result of the PROMID study, which prospectively compared octreotide LAR versus placebo among treatment-naïve patients with midgut NETs.<sup>53</sup> The study showed a significant improvement in time to progression (TTP) among patients treated with octreotide LAR (HR, 0.34; 95% CI, 0.2–0.59;  $P < 0.001$ ). The median TTPs among patients receiving octreotide LAR and placebo were 14.3 and 6.0 months, respectively. The PROMID study was not adequately powered to address overall survival. However, a study

of the large population-based SEER registries found a significant improvement in the overall survival of patients with metastatic NETs contemporaneous with the commercial introduction of octreotide in the United States.<sup>1</sup> Together, these results suggest octreotide LAR significantly improves TTP among patients with metastatic well-differentiated midgut NETs and should be considered an option for tumor stabilization among patients with or without carcinoid syndrome.

A similar study comparing lanreotide versus placebo is ongoing among patients with nonfunctional tumors. If positive, this would serve to confirm the disease-stabilizing effect of somatostatin analogs in NETs.

### Interferon

Interferon  $\alpha$  has been reported to induce disease stabilization and can lead to objective response in a small number of patients. Most of these studies, however, are underpowered. Pooling the data from patients with carcinoid involved in these trials, only 37 (12%) of 309 had objective tumor responses.<sup>54</sup>

Combining somatostatin analogs with IFN can theoretically enhance antitumor activity. Two underpowered random-assignment studies have attempted to compare single-agent and combination therapy. In a study, NET patients who have undergone debulking by surgery and hepatic artery embolization were randomly assigned to octreotide or octreotide plus IFN. A significant improvement in TTP was observed in the IFN arm (HR, 0.28; 95% CI, 0.16–0.45). In a second random-assignment trial, patients were treated with lanreotide, IFN, or lanreotide plus IFN. Objective response rates were 4%, 4%, and 7%. Although there is no defined standard therapy, in patients with progressive disease, octreotide plus IFN can be considered an accepted option.

### Chemotherapy

Unlike foregut NETs, there are few data to support the use of any existing cytotoxic chemotherapy agents in the treatment of midgut NETs. In the more recently reported Eastern Cooperative Oncology Group phase 3 study of chemotherapy in carcinoid tumors (E1281), patients were randomly assigned to treatment with 5-fluorouracil (5-FU) plus doxorubicin or 5-FU plus streptozocin. The median progression-free survival (PFS) durations were disappointing. Median PFS was 4.5 months in the 5-FU plus doxorubicin arm and was 5.3 months in the 5-FU plus streptozocin arm. Overall survival durations recorded in the trial were also suboptimal at 15 and 24 months, respectively. There is no clear survival benefit for cytotoxic chemotherapy. The use of cytotoxic chemotherapy should be considered only for patients who have exhausted standard and investigational therapy options.

### mTOR Inhibitors

mTOR is a conserved serine/threonine kinase that regulates cell growth and metabolism in response to environmental factors and signaling downstream of receptor tyrosine kinases, such as insulinlike growth factor receptor, VEGF receptor, and epidermal growth factor receptor. Both temsirolimus and everolimus have been studied in NETs. In the temsirolimus study, 37 patients with progressive NETs received temsirolimus intravenously at 25 mg/wk. The investigators found that temsirolimus had a modest clinical activity, with a response rate of 5.6% and median TTP of 6 months. The combination of octreotide LAR and everolimus was studied in 60 patients with NETs. Per-protocol response rate among patients with carcinoid tumors was 17%.<sup>55</sup> Median PFS duration was 63 weeks. RADIANT-2 is a randomized double-blind, placebo-controlled, multicenter phase 3 study of octreotide LAR with everolimus or placebo in patients with advanced carcinoid tumors. The study has completed accrual.

Although everolimus cannot yet be considered standard, it could be considered for patients without other options.

### VEGF Inhibitors

A number VEGF inhibitors, including monoclonal antibody bevacizumab and tyrosine kinase inhibitors, sunitinib and sorafenib, have been studied in NETs. In a random-assignment phase 2 study conducted at M. D. Anderson, rapid and sustained decrease in tumor perfusion after treatment with bevacizumab as measured using functional CT was observed.<sup>56</sup> Clinical activity was evidenced by a response rate of 18% and an improved PFS rate at week 18 (95% vs 68%;  $P = 0.02$ ).<sup>56</sup> A phase 3 study sponsored by the Southwest Oncology Group and the National Cancer Institute and supported by Cancer and Leukemia Group B, Eastern Cooperative Oncology Group, and North Central CTG through the Cancer Trials Support Unit will compare octreotide LAR and bevacizumab to octreotide LAR and IFN among patients with advanced carcinoid tumors (SWOG 0518, NCT00569127).

Phase 2 studies of VEGF receptor tyrosine kinase inhibitors that have stratified patients by pancreatic and nonpancreatic primary site have generally reported higher response rates among patients with pancreatic primary sites. However, carcinoid patients in these studies have also had minor responses and favorable PFS, indicating that these agents may be active. Phase 3 confirmatory studies are needed.

### Liver-Directed Therapy

The most frequent cause of death in patients with NETs is liver failure due to hepatic replacement by tumor. The goals of treatment include symptom control, biochemical control, objective tumor control, and improvement in quality of life.<sup>57</sup> Hepatic cytoreductive surgery can provide a long-lasting benefit. Options include formal hepatic lobe resections, nonanatomical metastasectomies, intraoperative radiofrequency ablation or cryoablation, or some combination thereof. In selected cases, liver transplant may be an option for patients in whom extrahepatic disease has been controlled or eliminated.<sup>57</sup> Generally accepted criteria for liver transplant candidacy include a favorable histological grade and low mitotic index and adequate physiologic/nutritional status. Because of the paucity of cadaveric organ donors, living liver donation is now a consideration.

Liver-directed cytoreduction can also be performed with minimally invasive, image-guided techniques. These include radiofrequency, cryoablation, and microwave ablation, as well as laser-induced interstitial thermotherapy. Thermal ablative therapies can be used percutaneously, treating with CT scan, ultrasound, or MRI guidance. These therapies are typically reserved for patients with relatively small tumor burden. Both percutaneous heating and freezing probes have been successful in providing local tumor control and palliating symptoms.<sup>58,59</sup>

Many patients have more extensive liver involvement and may require regional liver therapy. Regional arterial therapies are administered through angiographic catheters and can be delivered in a segmental, lobar, or whole-liver distribution. These include bland embolization, chemoembolization, radioactive microsphere embolization, and percutaneous hepatic perfusion. Particle embolization with or without chemotherapy has long been the standard therapy for patients with extensive liver involvement. Patients tend to develop postembolization syndrome (fever, pain, and nausea) after these procedures and require short-stay hospitalization.

Prospective random-assignment comparison of hepatic artery embolization and chemoembolization is lacking. Although data suggest that the addition of intra-arterial cytotoxic chemo-

therapy improves outcome for patients with pancreatic NETs,<sup>60</sup> there are conflicting data for patients with midgut NETs. Major reasons for the lack of agreement on this issue include the following:

- heterogeneous tumor populations in various studies and
- the use of different agents and regimens in different studies.

Thus, it is not likely that we will be able to answer the more general question of whether chemoembolization is better than bland embolization among patients with midgut NETs. Prospective studies are needed to compare specific chemoembolization regimens to bland embolization among patients with midgut NETs.

Radioactive microsphere embolization is emerging as a well-tolerated outpatient procedure providing symptom relief and encouraging response rates. Preliminary data with percutaneous hepatic perfusion using melphalan in patients with NET are also encouraging.<sup>61</sup> These regional treatments have also been used to render nonresectable tumors resectable in a small percentage of patients.

Sequencing of liver-directed therapy may affect efficacy and treatment options in the patient's future. Because the delivery of therapeutic particles largely depends on flow, therapy that alters flow patterns in these often hypervascular tumors (hepatic artery embolization or VEGF inhibitors) may affect how well subsequent agents delivered via the hepatic artery will reach the tumor vasculature. Further studies in this area are needed.

In general, these nonsurgical therapies are reserved for patients who have no surgical options. We recommend a multidisciplinary team approach to formulate a surgical and nonsurgical plan for each individual patient. Many patients have been safely cytoreduced using a multispecialty approach involving experienced interventional radiologists and hepatobiliary surgeons. Patients should be periodically reviewed for stability or progression of disease and surgical candidacy.<sup>57</sup>

### Peptide Receptor Radiotherapy

Clinical studies addressing targeted radionuclide therapy for NETs have primarily focused on the following 3 radioactive drugs: <sup>131</sup>I-metaiodobenzylguanidine [<sup>131</sup>I-MIBG (Azedra; Molecular Insight Pharmaceuticals, Cambridge, Mass)], <sup>90</sup>Y-DOTA-Phe<sup>1</sup>-Tyr<sup>3</sup>-Octreotide [<sup>90</sup>Y-DOTATOC (Onalta; Molecular Insight Pharmaceuticals)], and <sup>177</sup>Lu-DOTA-Tyr<sup>3</sup>-octreotate (<sup>177</sup>Lu-DOTATATE). Worldwide, there is greater experience with the radiolabeled octreotides <sup>90</sup>Y-DOTATOC and <sup>177</sup>Lu-DOTATATE than <sup>131</sup>I-MIBG. Overall response rates generally ranging from 20% to 30% have been reported for <sup>90</sup>Y-DOTATOC and <sup>177</sup>Lu-DOTATATE in the literature. These, however, should be interpreted with caution as many studies have not included intent-to-treat analysis, and randomized controlled studies are lacking. In general, the efficacy of targeted radionuclide therapy with these radioactive drugs will be limited by tumor radiation dose levels that are achievable without causing substantial toxicity to normal organs.

It is essential as a prerequisite to therapy to demonstrate sufficient tumor targeting using a "tracer" administration of the proposed therapeutic agent or its surrogate. It is recommended that [<sup>111</sup>In-DTPA<sup>0</sup>]octreotide scintigraphy be performed to assess the degree of uptake before somatostatin receptor-targeted radiotherapy. In general, levels of tumor uptake less than those seen in normal liver are considered inadequate for therapy. If it is ascertained that tumor uptake is inadequate for therapy with <sup>90</sup>Y-DOTATOC or <sup>177</sup>Lu-DOTATATE, imaging can next be performed with <sup>123</sup>I-MIBG to determine whether treatment with <sup>131</sup>I-MIBG might be reasonable.

## CONCLUSIONS

Midgut NETs varies in their presenting symptoms depending on stage and primary site. Local-regional NETs should be resected whenever possible. With the exception of small well-differentiated NET of the appendix, NETs of the midgut have a substantial risk of relapse after resection and need to be followed for at least 7 years.

Metastatic/advanced NETs of the midgut are incurable. Optimal management requires a multidisciplinary approach. Somatostatin analogs are effective in the management of carcinoid syndrome. Octreotide LAR has also recently been shown to delay disease progression. Liver-directed therapy and surgical debulking can improve quality of life in selected patients. Pivotal phase 3 studies with bevacizumab targeting VEGF and everolimus targeting mTOR are ongoing and may lead to improved outcome. Further studies of novel approaches such as PRRT are also warranted.

## REFERENCES

1. Yao JC, Hassan M, Phan A, et al. One hundred years after "carcinoid": epidemiology of and prognostic factors for neuroendocrine tumors in 35,825 cases in the United States. *J Clin Oncol*. 2008;26:3063–3072.
2. Berg JW, Godwin JD 2nd. The epidemiologic pathology of carcinomas of the large bowel. *J Surg Oncol*. 1974;6:381–400.
3. Moertel CG, Sauer WG, Docherty MB, et al. Life history of the carcinoid tumor of the small intestine. *Cancer*. 1961;14:291–293.
4. Surveillance, Epidemiology, and End Results (SEER) Program. SEER\*Stat Database: SEER 17 Regs Nov 2006 sub (1973–2004) (ed released April 2006). Available at: www.seer.cancer.gov. National Cancer Institute, DCCPS, Surveillance Research Program, Cancer Statistics Branch; 2006.
5. Hassan MM, Phan A, Li D, et al. Family history of cancer and associated risk of developing neuroendocrine tumors: a case-control study. *Cancer Epidemiol Biomarkers Prev*. 2008;17:959–965.
6. Hiripi E, Bermejo JL, Sundquist J, et al. Familial gastrointestinal carcinoid tumours and associated cancers. *Ann Oncol*. 2009;20:950–954.
7. Chen CC, Neugut AI, Rotterdam H. Risk factors for adenocarcinomas and malignant carcinoids of the small intestine: preliminary findings. *Cancer Epidemiol Biomarkers Prev*. 1994;3:205–207.
8. Chow WH, Linet MS, McLaughlin JK, et al. Risk factors for small intestine cancer. *Cancer Causes Control*. 1993;4:163–169.
9. Kaerlev L, Teglbjaerg PS, Sabroe S, et al. The importance of smoking and medical history for development of small bowel carcinoid tumor: a European population-based case-control study. *Cancer Causes Control*. 2002;13:27–34.
10. Hassan MM, Phan A, Li D, et al. Risk factors associated with neuroendocrine tumors: a U.S.-based case-control study. *Int J Cancer*. 2008;123:867–873.
11. Cross AJ, Leitzmann MF, Subar AF, et al. A prospective study of meat and fat intake in relation to small intestinal cancer. *Cancer Res*. 2008;68:9274–9279.
12. Schatzkin A, Park Y, Leitzmann MF, et al. Prospective study of dietary fiber, whole grain foods, and small intestinal cancer. *Gastroenterology*. 2008;135:1163–1167.
13. Tang LH, Shia J, Soslow RA, et al. Pathologic classification and clinical behavior of the spectrum of goblet cell carcinoid tumors of the appendix. *Am J Surg Pathol*. 2008;32:1429–1443.
14. Guo Z, Li Q, Wilander E, et al. Clonality analysis of multifocal carcinoid tumours of the small intestine by X-chromosome inactivation analysis. *J Pathol*. 2000;190:76–79.
15. Choi IS, Estecio MR, Nagano Y, et al. Hypomethylation of LINE-1 and Alu in well-differentiated neuroendocrine tumors (pancreatic endocrine tumors and carcinoid tumors). *Mod Pathol*. 2007;20:802–810.
16. Semelka RC, Custodio CM, Cem Balci N, et al. Neuroendocrine tumors of the pancreas: spectrum of appearances on MRI. *J Magn Reson Imaging*. 2000;11:141–148.
17. Pamuklar E, Semelka RC. MR imaging of the pancreas. *Magn Reson Imaging Clin N Am*. 2005;13:313–330.
18. Kelekis NL, Semelka RC. MRI of pancreatic tumors. *Eur Radiol*. 1997;7:875–886.
19. Dromain C, de Baere T, Baudin E, et al. MR imaging of hepatic metastases caused by neuroendocrine tumors: comparing four techniques. *Am J Roentgenol*. 2003;180:121–128.
20. Debray MP, Geoffroy O, Laissy JP, et al. Imaging appearances of metastases from neuroendocrine tumours of the pancreas. *Br J Radiol*. 2001;74:1065–1070.
21. Krenning EP, Kooij PPM, Bakker WH, et al. Radiotherapy with a radiolabeled somatostatin analogue, [<sup>111</sup>In-DTPA-D-Phe<sup>1</sup>]-octreotide. *Ann N Y Acad Sci*. 1994;733:496–506.
22. Balon HR, Goldsmith SJ, Siegel BA, et al. Procedure guideline for somatostatin receptor scintigraphy with (111)In-pentetreotide. *J Nucl Med*. 2001;42:1134–1138.
23. Orlefors H, Sundin A, Garske U, et al. Whole-body (11)C-5-hydroxytryptophan positron emission tomography as a universal imaging technique for neuroendocrine tumors: comparison with somatostatin receptor scintigraphy and computed tomography. *J Clin Endocrinol Metab*. 2005;90:3392–3400.
24. Goebel SU, Serrano J, Yu F, et al. Prospective study of the value of serum chromogranin A or serum gastrin levels in the assessment of the presence, extent, or growth of gastrinomas. *Cancer*. 1999;85:1470–1483.
25. Bernini GP, Moretti A, Ferdeghini M, et al. A new human chromogranin 'A' immunoradiometric assay for the diagnosis of neuroendocrine tumours. *Br J Cancer*. 2001;84:636–642.
26. Nehar D, Lombard-Bohas C, Olivieri S, et al. Interest of chromogranin A for diagnosis and follow-up of endocrine tumours. *Clin Endocrinol (Oxf)*. 2004;60:644–652.
27. Bajetta E, Ferrari L, Martinetti A, et al. Chromogranin A, neuron specific enolase, carcinoembryonic antigen, and hydroxyindole acetic acid evaluation in patients with neuroendocrine tumors. *Cancer*. 1999;86:858–865.
28. Tormey WP, FitzGerald RJ. The clinical and laboratory correlates of an increased urinary 5-hydroxyindoleacetic acid. *Postgrad Med J*. 1995;71:542–545.
29. Feldman J, Lee E. Serotonin content of foods: effect on urinary excretion of 5-hydroxyindoleacetic acid. *Am J Clin Nutr*. 1985;42:639–643.
30. Modlin IM, Lye KD, Kidd M. A 5-decade analysis of 13,715 carcinoid tumors. *Cancer*. 2003;97:934–959.
31. Oberg K, Astrup L, Eriksson B, et al. Guidelines for the management of gastroenteropancreatic neuroendocrine tumours (including bronchopulmonary and thymic neoplasms). Part I—general overview. *Acta Oncol*. 2004;43:617–625.
32. Honig LJ, Weingarten G. A gastric carcinoid tumor with massive bleeding. *Am J Gastroenterol*. 1974;61:40–44.
33. Kinney MA, Warner ME, vanHeerden JA, et al. Peri-anesthetic risks and outcomes of pheochromocytoma and paraganglioma resection. *Anesth Analg*. 2000;91:1118–1123.
34. Parris WC, Oates JA, Kambam J, et al. Pre-treatment with somatostatin in the anaesthetic management of a patient with carcinoid syndrome. *Can J Anaesth*. 1988;35:413–416.
35. Quinlivan JK, Roberts W. Intraoperative octreotide for refractory carcinoid-induced bronchospasm. *Anesth Analg*. 1994;78:400–402.
36. Claire RE, Drover DD, Haddow GR, et al. Orthotopic liver transplantation for carcinoid tumour metastatic to the liver: anesthetic management. *Can J Anaesth*. 2000;47:334–337.
37. Orbach-Zinger S, Lombroso R, Eidelman LA. Uneventful spinal anesthesia for a patient with carcinoid syndrome managed with long-acting octreotide. *Can J Anaesth*. 2002;49:678–681.
38. Anthony LB, Stafford S, Cronin M, et al. Octreotide LAR doses used in clinical practice: results from an internet survey and a clinical practice. In: Gary A, ed. *Annual Meeting of the American Society of Clinical Oncology*. New Orleans, LA: American Society of Clinical Oncology; 2004:381.

39. Rubin J, Ajani J, Schirmer W, et al. Octreotide acetate long-acting formulation versus open-label subcutaneous octreotide acetate in malignant carcinoid syndrome. *J Clin Oncol*. 1999;17:600–606.
40. Biesma B, Willemse PH, Mulder NH, et al. Recombinant interferon alpha-2b in patients with metastatic apudomas: effect on tumours and tumour markers. *Br J Cancer*. 1992;66:850–855.
41. Oberg K. Endocrine tumors of the gastrointestinal tract: systemic treatment. *Anticancer Drugs*. 1994;5:503–519.
42. Oberg K. The action of interferon alpha on human carcinoid tumours. *Semin Cancer Biol*. 1992;3:35–41.
43. Dirix LY, Vermeulen PB, Fierens H, et al. Long-term results of continuous treatment with recombinant interferon- alpha in patients with metastatic carcinoid tumors—an antiangiogenic effect? *Anticancer Drugs*. 1996;7:175–181.
44. Janson EM, Ahlstrom H, Andersson T, et al. Octreotide and interferon alfa: a new combination for the treatment of malignant carcinoid tumours. *Eur J Cancer*. 1992;10:1647–1650.
45. Smith DB, Scarffe JH, Wagstaff J, et al. Phase II trial of rDNA alfa 2b interferon in patients with malignant carcinoid tumor. *Cancer Treat Rep*. 1987;71:1265–1266.
46. Doberauer C, Mengelkoch B, Kloke O, et al. Treatment of metastatic carcinoid tumors and the carcinoid syndrome with recombinant interferon alpha. *Acta Oncol*. 1991;30:603–605.
47. Creutzfeldt W, Bartsch HH, Jacobaschke U, et al. Treatment of gastrointestinal endocrine tumours with interferon-alpha and octreotide. *Acta Oncol*. 1991;30:529–535.
48. Bajetta E, Zilembo N, Di Bartolomeo M, et al. Treatment of metastatic carcinoids and other neuroendocrine tumors with recombinant interferon-alpha-2a. A study by the Italian Trials in Medical Oncology Group. *Cancer*. 1993;72:3099–3105.
49. Di Bartolomeo M, Bajetta E, Zilembo N, et al. Treatment of carcinoid syndrome with recombinant interferon alpha-2a [published correction appears in *Acta Oncol* 32:592;1993]. *Acta Oncol*. 1993; 32:235–238.
50. Oberg K. Chemotherapy and biotherapy in the treatment of neuroendocrine tumours. *Ann Oncol*. 2001;12(suppl 2):S111–S114.
51. Shah T, Caplin M. Endocrine tumours of the gastrointestinal tract. Biotherapy for metastatic endocrine tumours. *Best Pract Res Clin Gastroenterol*. 2005;19:617–636.
52. Plockinger U, Rindi G, Arnold R, et al. Guidelines for the diagnosis and treatment of neuroendocrine gastrointestinal tumours. A consensus statement on behalf of the European Neuroendocrine Tumour Society (ENETS). *Neuroendocrinology*. 2004;80:394–424.
53. Rinke A, Muller HH, Schade-Brittinger C, et al. Placebo-controlled, double-blind, prospective, randomized study on the effect of octreotide LAR in the control of tumor growth in patients with metastatic neuroendocrine midgut tumors: a report from the PROMID Study Group. *J Clin Oncol*. 2009;27:4656–4663.
54. Schnirer II, Yao JC, Ajani JA. Carcinoid: a comprehensive review. *Acta Oncol*. 2003;42:672–692.
55. Yao JC, Phan AT, Chang DZ, et al. Efficacy of RAD001 (everolimus) and octreotide LAR in advanced low- to intermediate-grade neuroendocrine tumors: results of a phase II study. *J Clin Oncol*. 2008;26:4311–4318.
56. Yao JC, Phan A, Hoff PM, et al. Targeting vascular endothelial growth factor in advanced carcinoid tumor: a random assignment phase II study of depot octreotide with bevacizumab and pegylated interferon alpha-2b. *J Clin Oncol*. 2008;26:1316–1323.
57. Maroun J, Kocha W, Kvols L, et al. Guidelines for the diagnosis and management of carcinoid tumours. Part I: the gastrointestinal tract. A statement from a Canadian National Carcinoid Expert Group. *Curr Oncol*. 2006;13:67–76.
58. Vogl TJ, Naguib NN, Zangos S, et al. Liver metastases of neuroendocrine carcinomas: interventional treatment via transarterial embolization, chemoembolization and thermal ablation. *Eur J Radiol*. 2009;72: 517–528.
59. Siperstein AE, Berber E. Cryoablation, percutaneous alcohol injection, and radiofrequency ablation for treatment of neuroendocrine liver metastases. *World J Surg*. 2001;25:693–696.
60. Gupta S, Johnson MM, Murthy R, et al. Hepatic arterial embolization and chemoembolization for the treatment of patients with metastatic neuroendocrine tumors. *Cancer*. 2005;104:1590–1602.
61. Jones A, Alexander HR Jr. Development of isolated hepatic perfusion for patients who have unresectable hepatic malignancies. *Surg Oncol Clin N Am*. 2008;17:857–876, x.