

## NANETS Consensus Guidelines for the Diagnosis of Neuroendocrine Tumor

Aaron I. Vinik, MD, PhD,\* Eugene A. Woltering, MD,† Richard R. P. Warner, MD,‡  
Martyn Caplin, MD,§ Thomas M. O'Dorisio, MD,|| Gregory A. Wiseman, MD,¶  
Domenico Coppola, MD,# and Vay Liang W. Go, MD\*\*

Neuroendocrine tumors (NETs) are rare, slow-growing neoplasms characterized by their ability to store and secrete different peptides and neuroamines.<sup>1</sup> Some of these substances cause specific clinical syndromes,<sup>2</sup> whereas other may have elevated plasma or urine levels that are not associated with specific syndromes or symptom complexes. Unfortunately, there is no “ideal neuroendocrine tumor marker,”<sup>3</sup> but according to the presentation, the sensitivity and specificity of each marker vary, and it is generally possible to choose those of greatest value for each clinical syndrome.

The biochemical markers are those hormones or amines secreted by the neuroendocrine cells from which these tumors are derived. Some of these are not specific to any tumor, but are produced and secreted by most NETs, whereas other biochemical markers are more specific to the type of tumor and where their quantification can lead to the suspicion or confirmation of the presence of such a tumor.

The annual incidence of NETs has risen to 40 to 50 cases per million, perhaps because of better diagnosis and the availability of highly specific and sensitive ways to measure these tumors' products, improved immunohistochemistry, and enhanced techniques for tumor detection. Thus, the perceived increase in incidence may not be a real change in the incidence of the disease.

There are a number of impediments to the diagnosis of these tumors. They are rare, comprising less than 2% of gastrointestinal (GI) malignancies, and are therefore not high on the list of causes of specific symptom complexes. Symptoms themselves are often nonspecific and do not lend themselves readily to identifying the specific underlying tumor. In addition, the manifestations are protean and mimic a variety of disorders. Tumors may be found incidentally on laparoscopy for abdominal pain or during the surgical removal of an appendix or even during a computerized tomographic scan of the abdomen for unexplained symptoms. Lung carcinoids may present with hemoptysis or asthma-like symptoms, and midgut carcinoids may be confused with irritable bowel syndrome (IBS). The natural history of this disease is invariably attended by a long history of vague abdominal symptoms, a series of visits to a primary care practitioner, and referral to a gastroenterologist, often with a misdiagnosis of IBS. These symptoms persist with a median

latency to correct diagnosis of 9.2 years by which time the tumor has metastasized, causing symptoms such as flushing and diarrhea and progressing on its slow but relentless course until the patient dies. Clearly, a greater index of suspicion and a carcinoid tumor profile screen are warranted for all patients presenting with “traditional IBS symptoms.” Midgut carcinoids are associated with mesenteric fibrosis, which can compress mesenteric vessels and cause bowel ischemia and malabsorption, which may be found in the absence of an abdominal mass. The diagnosis of metastases to the liver is generally more obvious but often still takes place only after a delay of many years. Even then, an incorrect diagnosis is not uncommon. Unless biopsy material is examined for the secretory peptides chromogranin, synaptophysin, or neuron-specific enolase (NSE), tumors may be labeled erroneously as adenocarcinoma, with a negative impact on physician's attitudes regarding management and underestimation of prospects for survival.<sup>4</sup> The common symptomatic manifestations of patients with carcinoid tumors are illustrated in Tables 1 and 2.

### Flushing

It is vitally important to obtain a good history of the nature of the flushing to ascertain whether this can be ascribed to a NET. Is the flushing wet or dry? If dry, it is almost always due to a NET. If it is wet, it may still be due to a NET, but the diaphoresis is due to coexistent anxiety. Intermittent flushing suggests menopause or a NET, for example, systemic mastocytosis or pheochromocytoma. Constant flushing is found with alcoholism, polycythemia, and mitral valve disease, either stenosis or prolapse. If there is a facial rash, it may be rosacea, and if more diffuse, consider mastocytosis with the attendant dermatographia or dermatomyositis. If there are associated symptoms or signs such as diarrhea, this suggests a NET, either carcinoid or medullary carcinoma of the thyroid (MCT). Headache occurs with mastocytosis or pheochromocytoma, and syncope suggests autonomic neuropathy, pheochromocytoma, or epilepsy. Flushing in NETs is quite different depending on the location of the tumor.

### Foregut

The flushing in foregut carcinoid tumors is dry, long lasting, and intense and has a purplish or violet hue in contrast to the common red/pink hue seen in other NE-related flushing. It is related to telangiectasia and skin hypertrophy mostly in the face and upper neck but can also involve the limbs, and it can lead to a leonine appearance after repeated episodes.

### Midgut

In midgut tumors, it is faint pink to red and involves the face and upper trunk as far as the nipple line. The flush is initially provoked by exercise, alcohol, and food-containing tyramines (eg, blue cheese, chocolate, red sausage, and red wine). With time, the flush may occur spontaneously and without provocation. It usually is ephemeral, lasting only a few minutes, and may

From the \*Eastern Virginia Medical School, Strelitz Diabetes Center for Endocrine and Metabolic Disorders, Norfolk, VA; †Louisiana State University Health Sciences Center, New Orleans, LA; ‡Mt Sinai School of Medicine, New York, NY; §Royal Free Hospital London, London, UK; ||Holden Comprehensive Cancer Center University of Iowa, Iowa City, IA; ¶Mayo Clinic, Rochester, MN; #H. Lee Moffitt Cancer Center University of South Florida, Tampa, FL; and \*\*David Geffen School of Medicine, UCLA Los Angeles, CA.

Reprints: Aaron Vinik, MD, PhD, Eastern Virginia Medical School Strelitz Diabetes Research Center, 855 W Brambleton Ave, Norfolk, VA 3510 (e-mail: vinikai@evms.edu).

Copyright © 2010 by Lippincott Williams & Wilkins

**TABLE 1.** Clinical Presentations, Syndromes, Tumor Types, Sites, and Hormones<sup>4</sup>

Clinical Presentation	Syndrome	Tumor Type	Sites	Hormones
Flushing	Carcinoid	Carcinoid	Midgut/foregut, adrenal medulla, gastric	Serotonin, CGRP, calcitonin
	Medullary carcinoma of thyroid pheochromocytoma	C cell tumor Tumor of chromaffin cells	Thyroid C cells Adrenal and sympathetic nervous system	Metanephrine and normetanephrine
Diarrhea abdominal pain and dyspepsia	Carcinoid, WDHHA syndrome, ZES, PP, MCT	Carcinoid, VIPoma, gastrinoma, PPoma, medullary carcinoma thyroid, mastocytoma	As above, pancreas, mast cells, thyroid	As above, VIP, gastrin, PP, calcitonin
Diarrhea/steatorrhea	Somatostatin, bleeding GI tract	Somatostatinoma, neurofibromatosis	Pancreas, duodenum	Somatostatin
Wheezing	Carcinoid	Carcinoid	Gut/pancreas/lung	SP, CGRP, 5-HT
Ulcer/dyspepsia	ZES	Gastrinoma	Pancreas/duodenum	Gastrin
Hypoglycemia	Whipple triad	Insulinoma, sarcoma, hepatoma	Pancreas, retroperitoneal liver	Insulin, IGF-1, IGF-11
Dermatitis	Sweet syndrome, pellagra	Glucagonoma	Pancreas	Glucagon
		Carcinoid	Midgut	Serotonin
Dementia	Sweet syndrome	Glucagonoma	Pancreas	Glucagon
Diabetes	Glucagonoma	Glucagonoma	Pancreas	Glucagon
	Somatostatin	Somatostatinoma	Pancreas	Somatostatin
Deep vein thrombosis, steatorrhea, cholelithiasis neurofibromatosis	Somatostatin	Somatostatinoma	Pancreas	Somatostatin
			Duodenum	
Silent, liver metastasis	Silent	PPoma	Pancreas	PP

This table summarizes the suggested approach to diagnose a NET based on the clinical presentation, the tumor type, their sites of origin, and the possible means of diagnosis and the biochemical markers that should be measured.

CGRP indicates calcitonin gene-related peptide; WDHHA, watery diarrhea, hypokalemia, hyperchlorhydria, and acidosis.

occur many times per day; however, over many years, patients may develop a persistent flush with a purpuric malar and nasal complexion.

The differential diagnosis of flushing includes the postmenopausal state, simultaneous ingestion of chlorpropamide and alcohol, panic attacks, MCT, autoimmune epilepsy, autonomic neuropathy, and mastocytosis.<sup>5</sup> To differentiate all those causes from a carcinoid tumor, besides knowing the differences in the characteristics of the flushing, it is also necessary to know what is producing the flushing (Table 3).

Flushing in carcinoid syndrome has been ascribed to prostaglandins, kinins, and serotonin (5-HT). With the advent of sophisticated radioimmunoassay methods and region-specific antisera, a number of neurohumors now are thought to be secreted by carcinoid tumors, including 5-HT, dopamine, histamine, and 5-hydroxyindoleacetic acid (5-HIAA), kallikrein,

substance P, neurotensin, motilin, somatostatin, vasoactive intestinal polypeptide (VIP), prostaglandins, neuropeptide K, and gastrin-releasing peptide.

Several provocative tests have been developed to identify the cause of flushing in carcinoid syndrome. These tests are based on the need to distinguish the flushing from that found in a host of other conditions particularly in panic syndrome in which the associate anxiety and phobias usually establish the cause, but frequently, the physician and patient need reassurance that there is no underlying malignancy.

Feldman and O'Dorisio<sup>6</sup> have previously reported the incidence of elevated levels of plasma neuropeptide concentrations in patients with flushing. Despite the elevated basal concentrations of substance P and neurotensin, these authors were able to document further increases in these neuropeptides during ethanol-induced facial flushing.

**TABLE 2.** Clinical Presentation, Syndrome, Tumor Type of Ectopic Pancreatic Tumors, and the Hormones Produced

Clinical Presentation	Syndrome	Tumor Type	Sites	Hormones
Acromegaly	Acromegaly, Gigantism	NET	Pancreas islet	GHRH
Cushing	Cushing	NET	Pancreas islet	CRH, ACTH
Pigmentation	Pigmentation	NET	Pancreas islet	Melanocyte-stimulating hormone
Anorexia, nausea, vomiting, abdominal pain	Hypercalcemia	NET	Pancreas islet	PTH-rP

**TABLE 3.** Differential Diagnosis of Flushing and Recommended Tests

Clinical Condition	Tests
Carcinoid	Serotonin, 5-HIAA, NKA, TCP, PP, CGRP, VIP, SP, PGD <sub>2</sub> , PGE <sub>1</sub> , PGF <sub>2</sub>
MCT	Calcitonin, Ca <sup>2+</sup> infusion, RET protooncogene
Pheochromocytoma	CgA, plasma free metanephrines, urine metanephrines, VMA, epinephrine, norepinephrine, glucagon stimulation, MIBG
Diabetic autonomic neuropathy	HRV, 2hs PP glucose
Menopause	FSH
Epilepsy	EEG
Panic attack	Pentagastrin, ACTH
Mastocytosis	Plasma histamine, urine tryptase
Hypomastia and mitral valve prolapse	Cardiac echocardiogram

EEG indicates electroencephalography; FSH, follicle stimulating hormone; HRV, heart rate variability; PGD, prostaglandin D<sub>2</sub>; PGE, prostaglandin E.

Ahlman and colleagues<sup>7</sup> reported the results of pentagastrin (PG) provocation in 16 patients with midgut carcinoid tumors and hepatic metastases. All patients tested had elevated urinary 5-HIAA levels, and 12 had profuse diarrhea requiring medication. Pentagastrin uniformly induced facial flushing and GI symptoms in patients with liver metastases, but it had no effect in healthy control patients. All patients with PG-induced GI symptoms demonstrated elevated 5-HT levels in peripheral blood. Administration of a 5-HT-receptor antagonist had no effect on 5-HT release but completely aborted the GI symptoms. The authors emphasized the improved reliability of PG compared with calcium infusion, another provocative test popularized by Kaplan and colleagues,<sup>8</sup> and pointed out that PG provocation occasionally can be falsely negative in patients with subclinical disease. Vinik et al<sup>9</sup> reported that PG uniformly induced flushing in patients with gastric carcinoid tumors that was associated with a rise in circulating levels of SP in 80%. Thus, Substance P is a neurohumor that may be involved in the flushing of carcinoid syndrome.

Substance P has also been found in tumor extracts and plasma from patients with carcinoid tumors and, in 1 reported case, was useful for tumor localization. Neurokinin A (NKA), its amino-terminally extended form, neuropeptide K, and SP are a group of peptides (ie, tachykinins) with common biologic properties. Norheim and colleagues measured peptide responses to PG or ingestion of food or alcohol in 16 patients with metastatic carcinoid tumors and demonstrated 2-fold or greater increases in NKA and neuropeptide K in 75% of patients, as well as variable increases in SP in approximately 20% of patients.

Conlon and colleagues<sup>10</sup> used region-specific antisera to SP and NKA to measure circulating tachykinins during a meal-induced flush in 10 patients with metastatic carcinoid tumors. Five patients had undetectable levels of NKA and SP after stimulation, thus suggesting that elevated tachykinin concentrations are not a constant feature of such patients. The authors also studied the effect of a somatostatin-analog administration on meal-induced tachykinin responses in 3 patients with carcinoid tumors. Flushing was aborted in 2 patients, but tachykinin levels were only partially suppressed, indicating that these peptides

cannot be solely responsible for the carcinoid flush. When the diagnosis of the underlying cause of flushing has been established, pathogenesis-oriented treatment can be very helpful.<sup>5</sup>

Janet et al also performed a study, in which they used patients with metastasizing ileocecal 5-HT-producing carcinoid tumors and looked for the relationship of flushing to tachykinin production. They concluded that metastasizing ileocecal 5-HT-producing carcinoids produce many biologically active substances with partially overlapping biological functions. The biological processes underlying the specific symptoms of the carcinoid syndrome are probably multifactorial. They confirmed results from earlier studies showing that tachykinins and 5-HIAA levels are elevated in patients with daily episodes of flushing. The hormone effects were not mutually independent. It is possible that the development of flushing is the result of multihormonal stimulation. Other biologically active substances, such as kallikrein, and prostaglandins, may also contribute.<sup>11</sup>

### Diarrhea, Abdominal Pain, Dyspepsia

The key question to ask is whether the diarrhea persists with fasting. Diarrhea of NETs is always secretory, whereas diarrhea from other GI causes is usually malabsorptive. Perhaps the most vexing question is to differentiate the diarrhea and abdominal pain and dyspepsia from IBS. Irritable bowel syndrome affects a large proportion of the American population (6%–12%), and in Pakistan, Mexico, and Brazil, it may be as high as 40%. Abdominal pain and discomfort are the most prominent symptoms prompting consultation with a physician. Irritable bowel syndrome occurs more frequently in young white females, beginning before the age of 35 years in 50% of cases, and the symptoms typically do not disturb sleep, quite unlike that of NETs. Bleeding, fever, weight loss, and persistent severe pain are not features of IBS. Most sufferers (7.4%) report alternating constipation and diarrhea distinguishing them from NETs, and the diarrhea does not persist with fasting. Secretory diarrhea is characteristic of NETs, causing large-volume stools, and persists with fasting, and there is no osmotic gap between serum and stool. There are several causes of secretory diarrhea that need to be taken into consideration in the differential diagnosis: watery diarrhea, hypokalemia, hyperchlorhydria, and acidosis syndrome, the Zollinger-Ellison syndrome (ZES), carcinoid tumors, MCT, secreting villous adenoma of the rectum, surreptitious laxative abuse, and idiopathic. Diarrhea that disappears with the use of a proton pump inhibitor (PPI) is very suggestive of a gastrinoma because acid overproduction precipitates bile salts; inactivates lipase, amylase, and trypsin; and damages the intestinal mucosa. Another confounding issue is the change in the character of the diarrhea from a secretory diarrhea to a malabsorptive one with the use of somatostatin analogs. The stools become foul smelling; there is an inability to flush the toilet; and the stools float on the surface of the water and contain undigested food particles because somatostatin analogs cause inhibition of pancreatic enzyme secretion and the intestinal absorption of fluid and nutrients.

Neuroendocrine tumors can produce diarrhea by different mechanisms, depending on their secretory products. Gastrin can increase the acid secretion by the stomach, which in turn inactivates lipase, amylase, and trypsin and damages the mucosa of the small bowel, leading to decreased absorption and impaired digestion in the small bowel, exceeding the absorptive capacity of the colon, what gives an increased fecal volume and malabsorptive syndromes and sometimes steatorrhea. On the other hand, carcinoid or other NETs can produce other substances such as VIP, pancreatic polypeptide (PP), SP, calcitonin gene-related peptide, and/or thyrocalcitonin, all of which will act on the small bowel increasing the secretion of fluids and ions,

which in turn will also exceed the colonic absorptive capacity, producing an increased fecal volume as well as a great losses of potassium and bicarbonate.

A disturbing cause of diarrhea that may be very difficult to detect is laxative abuse, and, in all circumstances, a KOH stool preparation to detect laxatives is mandatory. Measurement of intestinal secretion by passing a multilumen tube and quantifying electrolytes and water transport, in addition to the measurement of stool electrolytes, which should account for the total osmolarity, will help to exclude laxative abuse but is rarely performed.

It is important to mention that Janet et al found, in their study of tachykinins and NETs, that there is an association between the elevation of tachykinins and the severity of the diarrhea. They concluded that all biochemical markers concentrations were elevated in patients with daily episodes of diarrhea, although the association between increased plasma tachykinins and the severity of diarrhea was independent of both chromogranin A (CgA) and 5-HIAA concentrations.<sup>11</sup>

### Bronchoconstriction

Wheezing due to bronchospasm occurs in up to one third of patients with carcinoid syndrome. Lung function tests show a prolonged forced expiratory volume in the first second. Differential diagnoses are asthma and chronic obstructive pulmonary disease. In the carcinoid syndrome, the cause of bronchoconstriction is usually substance P, histamine, or 5-HT that should be measured in patients who present with this symptom.<sup>4</sup>

### Dyspepsia or Peptic Ulcer

The ZES is characterized by peptic ulcers and diarrhea that responds to therapy with PPIs, in the setting of hypergastrinemia and low gastric pH. Gastrinomas are localized 90% of the time in the "gastrinoma triangle." As discussed in the previous section, the measurements that should be drawn for these tumors are fasting serum gastrin (FSG) and gastric acid output and, to differentiate gastrinoma from other cause of hypergastrinemia, a secretin- or calcium-stimulated gastrin.

### Hypoglycemia

The Whipple triad (symptoms of hypoglycemia, low blood glucose levels <40 mg/dL, and relief of symptoms with glucose) is the clinical presentation of insulinomas, but other causes should be ruled out. Patients with noninsulinoma pancreatogenous hypoglycemia syndrome present with postprandial neuroglycopenia symptoms (within 4 hours of meal ingestion) and have negative 72 hours fasting test and negative tumor localization studies, and on histological diagnosis, hypertrophy or nesidioblastosis rather than an insulinoma is found.<sup>12,13</sup> Other possible causes that should be thought of are fasting, autoimmune (insulin antibodies), counter-regulatory hormone deficiency, drug-induced and factitious hypoglycemia. To exclude all the other causes, clinical suspicion together with measurement of hormones or peptides should be used.

In the case of hypoglycemia, the recommended biochemical markers are insulin, insulin-like growth factor 2 (IGF-2), C-peptide, glucagon-like peptide type 1 (GLP-1), glucose dependent insulin releasing peptide, sulfonylurea, adrenocorticotrophic hormone (ACTH), growth hormone (GH), insulin antibodies, and liver enzymes.<sup>4</sup>

### Dumping Syndrome

This manifestation occurs after surgery when the pylorus has been resected or inactivated. It can be early, when symptoms resemble shock, or late, which presents as hypoglycemia. For the

diagnosis of this syndrome, a provocative test is done, giving the patient a high-calorie, carbohydrate-rich breakfast with 750 kcal (21 g protein, 30 g fat, and 99 g carbohydrate) that should be ingested in 10 minutes to produce the maximum response. After completion of the meal, blood sample is collected at 10, 15, 30, 45, 60, 120, and 180 minutes; to measure glucose, insulin, C-peptide, motilin, PP, and GLP-1 levels.<sup>4</sup> An exaggerated insulin and GLP-1 response to the meal is found in gastric bypass patients with the syndrome, although the case and relationship between the hormonal overproduction and the clinical syndrome remain controversial.

### Pellagra

Pellagra is caused by the deficiency of niacin due to the detour of the tryptophan pathway toward the production of increased amounts of 5-HT.

### DIAGNOSIS OF GASTRIC CARCINOID TUMORS

Fasting serum gastrin levels are important to differentiate types 1 and 2 gastric carcinoids from type 3. Gastrin levels are elevated in both types 1 and 2 gastric carcinoids but not in type 3. It is important to note that patient with type 1 gastric carcinoid are hypochlorhydric or achlorhydric, whereas patients with type 2 gastric carcinoids have high acid levels. 5-Hydroxyindoleacetic acid levels are generally not useful in patients with gastric carcinoid tumors, because development of the carcinoid syndrome is uncommon.<sup>14</sup> Furthermore, carcinoid syndrome, if it occurs in these patients, is reported to be characteristically atypical with normal 5-HT and 5-HIAA levels, although a recent study reports that the typical carcinoid syndrome can occur in rare patients with gastric carcinoids.<sup>1</sup> Plasma CgA levels are recommended because CgA is frequently elevated in both patients with types 1 and 2 and type 3 gastric carcinoid tumors,<sup>16</sup> and changes in CgA levels may be helpful in follow-up.<sup>16</sup> Chromogranin A should be used with caution as a marker of disease activity in patients treated with somatostatin analogs, because these agents significantly reduce plasma CgA levels, a change that may be more reflective of changes in hormonal synthesis and release from tumor cells than an actual reduction in tumor mass.<sup>16,17</sup> In patients on stable doses of somatostatin analogs, consistent increases in plasma CgA levels over time may reflect loss of secretory control and/or tumor growth. Plasma CgA levels have also been shown to have prognostic value in patients with metastatic disease.<sup>16,18</sup>

### PATHOLOGY

Neuroendocrine tumors arise throughout the body and share certain basic characteristics. It is suggested that all tumors are classified according to site, differentiation (well vs poorly differentiated); a marker of cell proliferation, for example, Ki-67; grade and stage; and hormones or amines produced and markers of behavior such as CgA and synaptophysin. Tumor differentiation refers to the extent of resemblance to the normal cellular counterpart or loss of this resemblance. Thus, NETs may be well or poorly differentiated. Tumor grade refers to the degree of biological aggressiveness; this may be related to differentiation but not necessarily so. Tumor stage refers to the extent of spread of the tumor. The extent of invasion into the organ of origin and involvement of nodes or distant sites are critical factors. There are a number of different systems to classify, grade, and stage NETs, and although the criteria differ among systems, the underlying basic data are similar. A review of nomenclature, grading, and staging system has been summarized in previous articles on the pathological classification of NETs adapted by the development of the NANETS Consensus Guidelines.

## IMMUNOHISTOCHEMISTRY

Although most agree that a mitotic rate or Ki-67 is necessary in specific cases, whether Ki-67 staining is needed in all cases remains hotly debated. An experienced pathologist familiar with NETs will likely be able to determine the tumor's grade in most resected specimens, and a Ki-67 can be obtained as needed in difficult cases. In small biopsy specimens, there may not be sufficient material to differentiate between grade 1 versus 2 neuroendocrine carcinomas with or without Ki-67. This marker can be helpful when there is large amount of crush artifact in grading these tumors.

## SPECIAL PATHOLOGICAL CONSIDERATION AMONG NETS OF THE MIDGUT

In addition to classic NETs, mixed histology tumors having neuroendocrine as well as glandular features, such as goblet cell carcinoids and adenocarcinoids, can be observed. Among midgut tumors, these are more frequent in the appendix and cecum. For example, mixed histology tumors account for 1% of jejunal/ileal NETs and 7.3% of cecal NETs ( $P < 0.001$ ).<sup>19</sup> Although the number of fraction of appendiceal NETs having mixed histology tumors in the Surveillance, Epidemiology, and End Results registry is even higher, the exact percentage is difficult to ascertain. This is due to the fact that small appendiceal carcinoids are often considered benign and not reported to the registries, and mixed histology tumors such as goblet cell carcinoids are generally considered malignant and more likely to be reported.

Similarly, the distribution of poorly differentiated NETs among midgut tumor is different. Poorly differentiated NETs account for only 0.9% and 1.1% of appendiceal and jejunal/ileal NETs, respectively. They, however, account for 14.2% of NETs arising from the cecum.<sup>19</sup>

These pathological descriptors provide important information for patient management as mixed histology tumors such as goblet cell can be more aggressive and prone to peritoneal dissemination. Poorly differentiated NETs are often rapidly progressive and require cytotoxic chemotherapy (see separate article).

## MOLECULAR GENETICS

The genetics of neuroendocrine tumorigenesis have yet to be elucidated. Although small familial clusters of midgut carcinoids have been described, there are no known genetic cancer syndromes associated with the development of midgut NETs. Tumors have clustered in several small families without multiple endocrine neoplasia type I (MEN I), and multiplicity of tumors is a feature on a quarter of isolated cases. Among sporadic midgut carcinoids, several studies examining the genetics of ileal carcinoid tumors using comparative genomic hybridization or microsatellite markers have shown frequent allelic deletion of chromosome 18.<sup>20,21</sup> On an epigenetic level, midgut NETs have been found to have global hypomethylation.<sup>22</sup> There are few data about genetic aspects in NETs of the appendix or cecum. Tumor multiplicity is much less frequent in the appendix and cecum than the ileum.

## BLOOD AND URINE BIOMARKERS IN MIDGUT NETS

Several circulating tumor markers have been evaluated for the follow-up management of NETs. Although these can be very useful for follow-up, isolated elevation of marker levels is generally not sufficient for diagnosis without tissue confirmation. The most important of these markers, CgA, is a 49-kd acidic

polypeptide that is widely present in the secretory granules of neuroendocrine cells. Plasma CgA is elevated in 60% to 100% of patients with either functioning or nonfunctioning NETs. The sensitivities and specificities of CgA for the detection of NETs range between 70% and 100%.<sup>23–26</sup> Chromogranin A level may correlate with tumor volume, but care should be taken in measuring CgA and interpreting the results. For example, because somatostatin analogs are known to affect blood levels of CgA, serial CgA levels should be measured at approximately the same interval from injection in patients receiving long-acting somatostatin analogs. Spuriously elevated levels of CgA have also been reported in patients using PPIs, in patients with renal or liver failure, and in those patients with chronic gastritis.

Urinary 5-HIAA (24-hour collection) is a useful laboratory marker for carcinoid tumors. It is a surrogate measure of 5-HT metabolism that tightly linked to the presence of carcinoid syndrome. It is also perhaps more useful than the direct measurement of 5-HT as serum 5-HT varies considerably during the day according to activity and stress level. The specificity of this test has been reported to be 88%.<sup>27</sup> However, certain foods and medications can increase urinary 5-HIAA levels and should be avoided during specimen collection.<sup>28</sup> High 5-HT concentrations occur with the ingestion of bananas, kiwis, pineapple, plantains, plums, and tomatoes. Moderate elevations are found with avocado, black olives, spinach, broccoli, cauliflower, eggplant, cantaloupe, dates, figs, grapefruit, and honeydew melon. Drugs that can increase 5-HIAA are acetanilide, phenacetin, reserpine, glyceryl guaiacolate (found in many cough syrups), and methocarbamol. Drugs that can decrease 5-HIAA levels include chlorpromazine, heparin, imipramine, isoniazid, levodopa, monoamine oxidase inhibitors, methenamine, methylodopa, phenothiazines, promethazine, and tricyclic antidepressants. Thus, there are a variety of confounding factors in the measurement of 5-HT and its metabolite, 5-HIAA, in addition to the fact that foregut carcinoids do not produce 5-HIAA but rather only 5HTP, limiting the usefulness of these measures as a diagnostic or screening tool.

Another useful blood marker, NSE, is a dimer of the glycolytic enzyme enolase. Neuron-specific enolase is present in the cytoplasmic compartment of the cell, and its serum level is thought to be unrelated to the secretory activity of the tumor.<sup>26</sup> Although it is less specific than CgA, it may be a useful marker for follow-up of patients with a known diagnosis of NETs.

A variety of other secreted molecules can be measured among patients with midgut NETs. These include other chromogranins such as chromogranins B and C, pancreastatin, and substance B. The general principle of biomarker measurement is to identify a few biomarkers that are elevated in the particular patient in question and follow these over time. It is generally not necessary to check every biomarker at every visit.

## PANCREATIC NETS

Pancreatic NETs (PNETs) have an estimated incidence of less than 1 per 100,000 individuals.<sup>29–31</sup> Pancreatic NETs are divided into 2 groups: those associated with a functional syndrome due to ectopic secretion of a biologically active substance and those that are not associated with a functional syndrome (generally called nonfunctional PNETs [NF-PNETs]).<sup>29–32</sup> This distinction is important for clinical presentation, diagnosis, and treatment of these tumors. Functional PNETs include insulinomas, gastrinomas, VIPomas, somatostatinomas, glucagonomas, GH-releasing factor-secreting (GRFomas), and a group of less common PNETs including PNETs secreting ACTH (ACTHomas) and causing Cushing syndrome, PNETs causing the carcinoid

syndrome, PNETs causing hypercalcemia, and very rarely PNETs ectopically secreting luteinizing hormone, rennin, or erythropoietin.<sup>29</sup> Functional PNETs and NF-PNETs also frequently secrete a number of other substances (chromogranins, NSE, subunits of human chorionic gonadotropin, neurotensin, ghrelin), but they do not cause a specific hormonal syndrome.<sup>29–32</sup> In terms of relative frequency, NF-PNETs are at present the most frequently found PNET, occurring approximately twice as frequently as insulinomas, which are generally more frequent than gastrinomas, following by glucagonomas > VIPomas > somatostatinomas > others.<sup>29,30,32,33</sup>

Pancreatic NETs can occur both sporadically and in patients with various inherited disorder.<sup>25,30</sup> Pancreatic NETs occur in 80% to 100% of patients with MEN I; in 10% to 17% of patients with von Hippel-Lindau syndrome (VHL); up to 10% of patients with von Recklinghausen disease (neurofibromatosis type 1 [NF-1]), and occasionally in patients with tuberous sclerosis.<sup>34</sup> Each of these is an autosomal dominant disorder.<sup>34</sup> Of these disorders, MEN I is the most frequent, in patients with PNETs.<sup>34,35</sup> Multiple endocrine neoplasia type I is caused by mutations in chromosome 11q13 region resulting in alterations in the MEN I gene, which encodes for a 610-amino acid nuclear protein, menin, which has important effects on transcriptional regulation, genomic stability, cell division, and cell cycle control.<sup>34</sup> Patients with MEN I develop hyperplasia or tumors of multiple endocrine and nonendocrine tissues including parathyroid adenomas (95%–100%) resulting in hyperparathyroidism, pituitary adenomas in 54% to 65%, adrenal adenomas (27%–36%), various carcinoid tumors (gastric, lung, thymic) (0%–10%), thyroid adenomas (up to 10%), various skin tumors (80%–95%), central nervous system tumors (up to 8%), and smooth muscle tumors (up to 10%).<sup>34</sup> In MEN I patients, 80% to 100% develop pancreatic NF-PNETs, but in most patients, they are small and microscopic, causing symptoms in only 0% to 13%.<sup>34</sup> Gastrinomas (>80% duodenal) develop in 54% of MEN I patients; insulinomas develop in 18%, and glucagonomas, VIPomas, GRFomas, somatostatinomas in less than 5%.<sup>34</sup> In VHL, 98% of all the PNETs that develop in 10% to 17% of the patients are NF-PNETs, in 0% to 10% of NF-1 patients developing a PNET, they are characteristically duodenal somatostatinomas, which do not cause the somatostatinoma syndrome, and in tuberous sclerosis, rare functional and NF-PNETs are reported.<sup>34</sup>

## INSULINOMA

Insulinoma patients characteristically present with symptoms of hypoglycemia, especially neuroglycopenic symptoms (confusion, altered consciousness) and symptoms due to sympathetic overdrive (weakness, sweating), which are usually made worse by fasting.<sup>29,36,37</sup> The diagnosis of insulinoma can be established by determining plasma proinsulin, insulin, C-peptide, and glucose levels, which are usually performed during a 72-hour fast.<sup>25,32,33</sup> It is important to realize that insulin levels are increasingly being determined by immunochemiluminescent assays or specific immunoradiometric assays that do not cross-react with proinsulin and give lower values than that obtained with most insulin radioimmunoassays, which can effect the proposed criteria listed in many reviews for diagnosis, which were based on radioimmunoassay results.<sup>29</sup>

There are 6 criteria for the diagnosis of insulinomas: documented blood glucose levels 2.2 mmol/L or less ( $\leq 40$  mg/dL), concomitant insulin levels 6  $\mu$ U/mL or greater ( $\geq 36$  pmol/L;  $\geq 3$   $\mu$ U/mL), C-peptide levels 200 pmol/L or greater, proinsulin levels 5 pmol/L or greater,  $\beta$ -hydroxybutyrate levels 2.7 mmol/L or less, and absence of sulfonyleurea (metabolites) in the plasma

and/or urine. Further controlled testing under supervision includes the 72-hour fast, which is the criterion standard for establishing the diagnosis of insulinoma.<sup>37</sup> Actually, 98% of patients with insulinomas will develop symptomatic hypoglycemia within 72 hours.<sup>1</sup> When the patient develops symptoms and the blood glucose levels are 2.2 mmol/L or less ( $\leq 40$  mg/dL), blood should also be drawn for C-peptide, proinsulin, and insulin and the fast should be stopped. Failure in appropriate insulin suppression in the presence of hypoglycemia substantiates an autonomously secreting insulinoma.<sup>37</sup> It has been proposed that the sensitivity of the 48-hour fasting test is between 94.5% and 95.7% and should be enough for the diagnosis of insulinoma instead of the 72-hour-fast test.<sup>38,39</sup> In the case of suspected insulinoma, it is important to keep in mind the possible differential diagnosis: nesidioblastosis, noninsulinoma pancreatogenous hypoglycemia syndrome (see discussion later), and multiple adenomas.

Insulinomas have an estimated annual incidence of 1 to 4 per million persons. Approximately 4% to 5% of patients with insulinoma have MEN I.<sup>34</sup> Insulinomas are usually single tumors (except in patients with MEN I), generally small (ie, <1 cm), and almost always (>99%) intrapancreatic in location and, in contrast to all other PNETs, are benign in more than 85% to 90% of patients.<sup>34,36,37,40</sup>

## GASTRINOMA

Patients typically present with abdominal pain due to peptic ulcer disease (PUD), diarrhea, and reflux esophagitis.<sup>41</sup> Zollinger-Ellison syndrome should be suspected in patients with PUD with diarrhea, with ulcers in unusual locations, with severe PUD or with complications of PUD, with PUD without *Helicobacter pylori* present, with PUD with a family history of PUD or endocrinopathies, or with PUD with prominent gastric folds, presence of an endocrinopathy or with hypergastrinemia.<sup>29,41–44</sup> The diagnosis of ZES requires the demonstration of inappropriate hypergastrinemia (ie, hypergastrinemia present at time of acid hypersecretion).<sup>29,41–44</sup> When ZES is suspected, the initial determination in most centers is a fasting gastrin level, because it will be elevated in 99% to 100% of ZES patients.<sup>29,43,44</sup> The diagnosis can be complicated by the fact that other conditions, some of which are much more common than ZES, can cause hypergastrinemia in a range seen with ZES patients.<sup>29,41–46</sup> These other conditions either can result in hypergastrinemia because of their causing hypochlorhydria/achlorhydria (atrophic gastritis, PPI treatment) or can be associated with increased acid secretion similar to ZES.<sup>29,41,43,44,47</sup> Recent studies<sup>47,48</sup> show the widespread use of PPIs can particularly complicate and delay the diagnosis of ZES. This occurs because PPIs, in contrast to histamine H<sub>2</sub>-receptor antagonists, control the symptoms in most ZES patients with conventional doses used to treat idiopathic PUD/esophagitis and thus mask the diagnosis.<sup>29,44,47</sup> Furthermore, PPIs cause hypergastrinemia in patients without ZES, commonly in the range that is seen with the majority of ZES patients.<sup>29,47–49</sup> For these measures, a washout period from PPIs treatment of 1 week is recommended.<sup>42</sup> If the FSG is 1000 ng/L or greater (pg/mL) and the gastric pH is less than 2.5, the diagnosis is established,<sup>1</sup> if the patient is normocalcemic and free of pyloric obstruction and has normal renal function.<sup>13</sup> The 2006 European Neuroendocrine Tumor Society (ENETS) guidelines had cutoff values of greater than 10-fold elevation for FSG and gastric pH 2 or less.<sup>42</sup> To exclude physiological hypergastrinemia (associated with hypochlorhydria/achlorhydria), it is essential to measure gastric pH when hypergastrinemia is detected because it is 2 or less in all patients with ZES not taking antisecretory drugs.<sup>50</sup> Because of the presence of other conditions that can also cause hypergastrinemia and an acidic pH, the diagnosis of ZES may require the

assessment of basal acid output as well as a secretin provocative gastrin test.<sup>29,42,44,45</sup> Gastrinomas ectopically express secretin receptors, and intravenous administration of secretin characteristically causes an exaggerated release of secretin by the gastrinoma ( $\geq 120$ -pg/mL increase postsecretin is positive to gastrinoma,<sup>45</sup> if the patient is not taking PPIs).<sup>45,51</sup> In the case that the FSG values are not high enough to make a definitive diagnosis, then a provocative test should be done. Administration of secretin after an overnight fast is performed, serum for estimation of gastrin levels is collected fasting and 2, 5, 10, 15, and 30 minutes after the secretin bolus. In healthy people, the increase in gastrin is not higher than 50% over the baseline level; in the presence of a gastrinoma, the increase is greater than 100 ng/L above the baseline levels, which will also distinguish patients with hypergastrinemia from those with achlorhydric states (ie, type I gastric carcinoids, use of PPIs, pernicious anemia, atrophic gastritis), who do not respond to the administration of secretin, unlike patients with a gastrinoma.<sup>4</sup>

With some patients suspected of having ZES, there can be risk to stopping PPIs to assess fasting gastrin levels and perform acid secretory studies or secretin provocative testing; thus, it is best that these patients be referred to a clinical unit experienced in making the diagnosis of ZES.

Currently gastrinomas, in contrast to older studies, are found in the duodenum in more than 60% of patients with sporadic ZES (>85% with MEN 1/ZES), are usually single in sporadic ZES and invariably multiple in MEN 1/ZES, are usually small in size in the duodenum (<1 cm), and are malignant in 60% to 90% of cases.<sup>34,52–56</sup> Recent studies show pancreatic tumors are more aggressive than duodenal tumors, are much more likely to metastasize to liver and/or bone, and are more likely to be present in the 25% of ZES patients with aggressive gastrinomas.<sup>34,52–56</sup>

The diagnosis of ZES in patients with MEN 1 can be complicated by the fact that the presence or absence of hyperparathyroidism with the resultant hypercalcemia can have a marked effect of fasting gastrin levels, basal acid output, and the secretin test results.<sup>34,35,60–62</sup> Each of these parameters can markedly decrease after correction of the hyperparathyroidism, by an effective parathyroidectomy ( $\geq 3.5$  glands removed), and thus can mask the diagnosis of ZES in a MEN 1 patient.<sup>30,31,56–58</sup>

## GLUCAGONOMA

### Glucagonoma or the "Sweet" Syndrome

Diabetes accompanied by the 4D syndrome (dermatosis: necrolytic migratory erythema, depression, deep venous thrombosis, and diarrhea) is the clinical presentation of glucagonomas. Glucagonomas cause glucose intolerance (40%–90%), weight loss (80%), and a pathognomonic rash characterized by a migratory necrolytic erythema (70%–90%).<sup>29,33,63–65</sup>

Glucose intolerance in the glucagonoma syndrome may relate to tumor size. Fasting plasma glucagon levels tend to be higher in patients with large hepatic metastases than in those without hepatic metastases,<sup>66</sup> and all patients with large hepatic metastases have glucose intolerance. Massive hepatic metastases may decrease the ability of the liver to metabolize splanchnic glucagon, thus increasing peripheral plasma glucagon levels. Glucagon may not directly induce hyperglycemia, however, unless metabolism of glucose by the liver is directly compromised. Another factor may be variation in the molecular species of glucagon that is present in each case and its biologic potency.<sup>10</sup>

Glucagonomas are generally single and large tumors (mean, 6 cm), associated with liver metastases in more than 60% of cases at diagnosis, and are almost entirely intrapancreatic in

location.<sup>29,33,63–65</sup> Although glucagonomas may be associated with glucose intolerance, clinically significant hyperglycemia occurs in only half of such patients. Patients with glucagonomas are frequently initially diagnosed by a dermatologist, after presenting with necrolytic migratory erythema. This rash, characterized by raised erythematous patches beginning in the perineum and subsequently involving the trunk and extremities, is found in more than two thirds of all patients.<sup>29,33,63–65</sup> However, necrolytic migratory erythema is not specific for glucagonomas because it can also occur in cirrhosis, pancreatitis, and celiac disease.<sup>29</sup> The diagnosis of a glucagonoma requires the demonstration of increased plasma glucagon levels (usually 500–1000 pg/mL, normal <50) in the presence of the appropriate symptoms.<sup>29,33,63–65</sup> In previously reported cases of glucagonoma in which plasma glucagon concentrations were measured by radioimmunoassay, fasting plasma glucagon concentrations were  $2100 \pm 334$  pg/mL. These levels are markedly higher than those reported in normal, fasting subjects (ie, 150 pg/mL) or in those with other disorders causing hyperglucagonemia, including diabetes mellitus, burn injury, acute trauma, bacteremia, cirrhosis, renal failure, or Cushing syndrome, where fasting plasma glucagon concentrations often are elevated but less than 500 pg/mL.

As with other islet cell neoplasms, glucagonomas may overproduce multiple hormones such as insulin, ACTH, PP, parathyroid hormone (PTH) or substances with PTH-like activity, gastrin, 5-HT, VIP, and melanocyte-stimulating hormone, in that order of frequency.<sup>67</sup>

## VIPOMAS

VIPomas are also called Verner-Morrison syndrome, pancreatic cholera, WDHA syndrome (for watery diarrhea, hypokalemia, and achlorhydria). VIPomas are PNETs ectopically secreting vasoactive intestinal polypeptide (VIP), which leads to profound, large-volume diarrhea (100% >700 mL/day), hypokalemia, and achlorhydria.<sup>29,31,33,63,68</sup> VIPomas are usually single tumors, metastatic at presentation in 70% to 80% of cases and in adults are intrapancreatic in location in more than 95% of cases, whereas in children they often are ganglioneuromas/ganglioblastomas.<sup>29,31,33,63,68</sup> The diagnosis requires the demonstration of an elevated plasma VIP level in a patient with large-volume secretory diarrhea.<sup>29,31,33,63,68</sup>

## SOMATOSTATINOMA

Somatostatin (SRIF) is a tetradecapeptide that inhibits numerous endocrine and exocrine secretory functions. Almost all gut hormones that have been studied are inhibited by SRIF, including insulin, PP, glucagon, gastrin, secretin, GIP, and motilin.<sup>69</sup> In addition to inhibition of the endocrine secretions, SRIF has direct effects on a number of target organs.<sup>70</sup> For example, it is a potent inhibitor of basal and PG-stimulated gastric acid secretion. It also has marked effects on GI transit time, intestinal motility, and absorption of nutrients from the small intestine. The major effect in the small intestine seems to be a delay in the absorption of fat and reduced absorption of calcium.

The salient features of the somatostatinoma syndrome are diabetes, diarrhea or steatorrhea, gallbladder disease, hypochlorhydria, and weight loss.<sup>71–73</sup> The first cases of the somatostatinoma syndrome were reported in 1977 by Ganda and colleagues.<sup>71</sup> We have examined the cases reported since 1977 and describe here the features now recognized to be a part of the syndrome. For convenience, we have divided the cases into those arising from the pancreas, the intestine, and extrapancreatic tumors. It seems that the syndrome differs among

tumors arising from the pancreas and the intestine or extrapancreatic sites. Therefore, these will be considered separately.

Most patients were between 40 and 60 years of age. There is a 2:1 ratio of female to male patients, which contrasts with the equal-sex incidence for other islet cell tumors.<sup>74</sup>

### PLASMA SOMATOSTATIN-LIKE IMMUNOREACTIVITY

The mean somatostatin-like immunoreactivity (SLI) concentration in patients with pancreatic somatostatinoma was 50 times higher than normal (range, 1–250 times). Intestinal somatostatins, however, had only slightly elevated or normal SLI concentrations.

### DIABETES MELLITUS AND HYPOGLYCEMIA

Seventy-five percent of patients with pancreatic tumors had diabetes mellitus. In contrast, diabetes occurred only in 11% of patients with intestinal tumors. In all instances, the diabetes was relatively mild and could be controlled with diet and/or oral hypoglycemic agents or with small doses of insulin. It is not clear, however, whether the differential inhibition of insulin and diabetogenic hormones can explain the usually mild degree of diabetes and the rarity of ketoacidosis in patients with somatostatinoma. Replacement of functional islet cell tissue by pancreatic tumor may be another reason for the development of diabetes in most patients with pancreatic somatostatinoma, contrasting with the low incidence in patients with intestinal tumors. These tumors usually are large and therefore destroy substantial portions of the pancreas.

### GALLBLADDER DISEASE

Fifty-nine percent of patients with pancreatic tumors and 27% of patients with intestinal tumors had gallbladder disease. The high incidence of gallbladder disease in patients with somatostatinoma and the absence of such an association in any other islet cell tumor suggest a causal relationship between gallbladder disease and somatostatinoma. Infusion of somatostatin into normal human subjects has been shown to inhibit gallbladder emptying,<sup>70,75</sup> suggesting that somatostatin-mediated inhibition of gallbladder emptying may cause the observed high rate of gallbladder disease in patients with somatostatinoma. This thesis is supported by the observation of massively dilated gallbladders without stones or other pathology<sup>76,77</sup> in patients with somatostatin-secreting tumors.

### DIARRHEA AND STEATORRHEA

Diarrhea consisting of 3 to 10 frequently foul-smelling stools per day and/or steatorrhea from 20 to 76 g of fat per 24 hours is common in patients with pancreatic somatostatinoma. This could result from the effects of high levels of somatostatin within the pancreas, serving as a paracrine mediator to inhibit exocrine secretion or, alternatively, from the somatostatinoma's causing duct obstruction. In some cases, the severity of diarrhea and steatorrhea parallels the course of the disease, worsening as the tumor advances and metastatic disease spreads and improving after tumor resection. Somatostatin has been shown to inhibit the pancreatic secretion of proteolytic enzymes, water, bicarbonate,<sup>78</sup> and gallbladder motility.<sup>79</sup> In addition, it inhibits the absorption of lipids.<sup>80</sup> All but 1 patient with diarrhea and steatorrhea had high plasma somatostatin concentrations. The rarity of diarrhea and/or steatorrhea in patients with intestinal somatostatins may result from the lower SLI levels.

### HYPOCHLORHYDRIA

Infusion of somatostatin has been shown to inhibit gastric acid secretion in human subjects.<sup>81</sup> Thus, hypochlorhydria in patients with somatostatinoma in the absence of gastric mucosal abnormalities likely results from elevated somatostatin concentrations. Basal and stimulated acid secretion was inhibited in 87% of patients with pancreatic tumors tested but in only 12% of patients with intestinal tumors.

### WEIGHT LOSS

Weight loss ranging from 9 to 21 kg over several months occurred in one third of patients with pancreatic tumors and one fifth of patients with intestinal tumors. The weight loss may relate to malabsorption and diarrhea, but in small intestinal tumors, anorexia, abdominal pain, and yet unexplained reasons may be relevant.

### ASSOCIATED ENDOCRINE DISORDERS

Of great interest is the presence of café au lait spots, neurofibromatosis, and paroxysmal hypertension in patients with intestinal tumors. Thus, approximately 50% of all patients have other endocrinopathies in addition to their somatostatinoma. Occurrence of MEN I has been recognized in patients with islet cell tumors, and MEN II-A or MEN II-B syndromes are present in association with pheochromocytomas and neurofibromatosis, respectively. It seems that an additional dimension of the duct associated tumors is MEN II. Secretion of different hormones by the same islet cell tumor, sometimes resulting in 2 distinct clinical disorders, is now being recognized with increasing frequency.<sup>82</sup> These possibilities should be considered during endocrine workups of patients with islet cell tumors and their relatives.

### TUMOR LOCATION

Of the reported primary tumors, 60% were found in the pancreas and 40% in the duodenum or jejunum. Of the pancreatic tumors, 50% were located in the head and 25% in the tail, and the remaining tumors either infiltrated the whole pancreas or were found in the body. Regarding extrapancreatic locations, approximately 50% originate in the duodenum, approximately 50% originate in the ampulla, and, rarely, one is found in the jejunum. Thus, approximately 60% of somatostatins originate in the upper intestinal tract, which probably is a consequence of the relatively large number of normal D cells in this region.

### TUMOR SIZE

Somatostatins tend to be large, similar to glucagonomas,<sup>83</sup> but unlike insulinomas and gastrinomas, which, as a rule, are small.<sup>84–86</sup> Within the intestine, tumors have tended to be smaller. Symptoms associated with somatostatins and glucagonomas are less pronounced and probably do not develop until very high blood levels of the respective hormones have been attained. As a result, somatostatins and glucagonomas are likely to be diagnosed later.

### INCIDENCE OF MALIGNANCY

Eighty percent of pancreatic patients with pancreatic somatostatins were metastatic at diagnosis, and 50% with intestinal tumors had evidence of metastatic disease. Metastasis to the liver is most frequent, and regional lymph node involvement and metastases to bone are less so. Thus, in approximately

70% of cases, metastatic disease is present at diagnosis. This is similar to the high incidence of malignancy in glucagonoma<sup>84</sup> and in gastrinoma,<sup>85</sup> but it is distinctly different from the low incidence of malignant in insulinoma.<sup>86</sup> The high prevalence of metastatic disease in somatostatinoma also may be a consequence of late diagnosis but apparently is not dependent on the tissue of origin.

### MICROSCOPIC APPEARANCE

On light microscopy, most tumors appear to be well-differentiated islet cell or carcinoid-type tumors. Some show a mixed picture, consisting of separate zones of differentiated and anaplastic cells. In the differentiated areas, cells are arranged in lobular or acinar patterns that are separated by fibrovascular stroma. Less well-differentiated areas consist of sheets of cells interrupted by fibrous septa.

Diffuse positive immunoreactivity for somatostatin usually is found, which contrasts with the rarity of somatostatin-positive cells in gastrinomas and other tumors. There is a unique occurrence of psammoma bodies in somatostatinomas localized within the duodenum. In addition, there is abundant immunologic evidence for the presence of cells containing insulin, calcitonin, gastrin and VIP, ACTH, prostaglandin E<sub>2</sub>, and SP. In tumors with multiple hormones, however, SLI-containing cells represent the large majority of all cells containing hormones detected by immunopathology.

### SOMATOSTATIN-CONTAINING TUMORS OUTSIDE THE GI TRACT

Somatostatin has been found in many tissues outside the GI tract. Prominent among those are the hypothalamic and extrahypothalamic regions of the brain, the peripheral nervous system (including the sympathetic adrenergic ganglia), and the C cells of the thyroid gland. Not surprisingly, therefore, high concentrations of somatostatin have been found in tumors originating from these tissues. Sano and colleagues<sup>87</sup> and Saito and colleagues<sup>88</sup> reported 7 patients with MTC who had high basal plasma SLI concentrations and high tumor SLI concentrations. Roos and colleagues<sup>89</sup> reported elevated plasma SLI concentrations in 3 of 7 patients with MTC and high tissue SLI concentrations in 3 of 5 MTC tumors. Some, but not all, of these patients exhibited the clinical somatostatinoma syndrome.

Elevated plasma SLI concentrations also have been reported in patients with small cell lung cancer.<sup>89</sup> One case of metastatic bronchial oat cell carcinoma caused Cushing syndrome, diabetes, diarrhea, steatorrhea, anemia, and weight loss and had a plasma SLI concentration 20 times greater than normal.<sup>90</sup> A patient with a bronchogenic carcinoma presenting with diabetic ketoacidosis and high levels of SLI (>5000 pg/mL) has been reported.<sup>91</sup> Pheochromocytomas<sup>82,92</sup> and catecholamine-producing extra-adrenal paragangliomas<sup>86</sup> are other examples of endocrine tumors producing and secreting somatostatin in addition to other hormonally active substances. One quarter of 37 patients with pheochromocytomas had elevated SLI levels.<sup>89</sup>

### DIAGNOSIS

In the reported series cited, somatostatinomas often were found more or less accidentally. In most cases, the tumors were found either during exploratory laparotomy or upper GI radiographic studies, computed tomography (CT), or ultrasound, or endoscopy performed because of various symptoms, including unexplained abdominal pain, melena, hematemesis, persistent diarrhea, or in search of insulinomas or ACTH-secreting tumors.

Once found, the tumors were identified as somatostatinoma by the demonstration of elevated tissue concentrations of SLI and/or prevalence of D cells by immunocytochemistry or demonstration of elevated plasma SLI concentrations. Thus, events leading to the diagnosis of somatostatinoma usually occur in reverse order. In other islet cell tumors, the clinical symptoms and signs usually suggest the diagnosis, which then is established by demonstration of diagnostically elevated blood hormone levels, following which efforts are undertaken to localize the tumors. It can be expected that the same sequence of diagnostic procedures will be followed in the future for the diagnosis of somatostatinoma, mainly for 2 reasons: (a) the increasing familiarity of physicians with the clinical somatostatinoma syndrome (this symptom complex, although not pathognomonic, is nevertheless sufficiently characteristic of somatostatinoma to suggest the correct diagnosis) and (b) the greater availability of reliable radioimmunoassays for the determination of SLI in blood has increased the yield. Presently, these assays are complicated by the need for cumbersome extraction procedures and are not readily available. (Assay available at Inter Science Institute: 800-255-2873.) It should be recognized, however, that the syndrome is rare. Of 1199 cases screened for somatostatinoma at the University of Michigan between 1982 and 1986, only 8 cases had diagnostic serum levels.

The diagnosis of somatostatinoma at a time when blood SLI concentrations are normal or only marginally elevated requires reliable provocative tests. Increased plasma SLI concentrations have been reported after intravenous infusion of tolbutamide and arginine, and decreased SLI concentrations have been observed after intravenous infusion of diazoxide. Arginine is a well-established stimulant for normal D cells and thus is unlikely to differentiate between normal and supranormal somatostatin secretion. The same may be true for diazoxide, which has been shown to decrease SLI secretion from normal dog pancreas as well as in patients with somatostatinoma.<sup>90</sup> Tolbutamide stimulates SLI release from normal dog and rat pancreas,<sup>78,79,93</sup> but no change was found in the circulating SLI concentrations of 3 normal human subjects after intravenous injection of 1 g of tolbutamide.<sup>94</sup> Therefore, at present, tolbutamide seems to be a candidate for a provocative agent in the diagnosis of somatostatinoma, but its reliability must be established in a greater number of patients and controls. Until then, it may be necessary to measure plasma SLI concentrations during routine work-ups for postprandial dyspepsia and gallbladder disorders,<sup>72</sup> for diabetes in patients without a family history, and for unexplained steatorrhea as these findings can be early signs of somatostatinomas.

Somatostatinomas are PNETs that can occur in the duodenum or pancreas.<sup>29,33,63,95,96</sup>

### OTHER RARE FUNCTIONAL PNETS

GRFomas ectopically secrete GH-releasing factor, which results in acromegaly, which is generally clinically indistinguishable from that caused by pituitary adenomas.<sup>29,63,97</sup> GRFomas in the pancreas are generally single, large tumors at diagnosis; one third have liver metastases, and they are found in the pancreas in 30% of cases, 54% in the lung, and the remainder primarily in other abdominal locations.<sup>29,63,97</sup> Pancreatic NETs causing hypercalcemia usually secrete PTH-related peptide (PTH-rP) as well as other biologically active peptides and are similar to pancreatic ACTHomas associated with ectopic Cushing syndrome in that both are usually large tumors at diagnosis, with 80% to 90% associated with liver metastases.<sup>29,63,98,99</sup> With ACTHomas or PNETs causing hypercalcemia, the diagnosis is made by the presence of a PET with the appropriated elevated hormonal assay result.

## NONFUNCTIONING PANCREATIC ENDOCRINE TUMORS

Nonfunctional PNETs are intrapancreatic in location, characteristically large (70% are >5 cm), and at an advanced stage when first diagnosed, with 60% to 85% having liver metastases in most series.<sup>29,31,32,63,100</sup> Because NF-PNETs are not associated with a clinical hormonal syndrome, they present clinically with symptoms due to the tumor per se, which include primarily abdominal pain (40%–60%), weight loss, or jaundice.<sup>29,31,32,63,100</sup> In recent years, NF-PNETs are increasingly being discovered by chance on imaging studies being performed for various non-specific abdominal symptoms.<sup>29,101</sup> Even though NF-PNETs do not secrete peptides causing a clinical syndrome, they are not biologically inactive, because they characteristically secrete a number of other peptides, which are frequently used in their diagnosis. These include chromogranins, especially CgA (70%–100%) and PP (50%–100%).<sup>29,31,32,63,100</sup> The presence of an NF-PET is suggested by the presence of a pancreatic mass in a patient without hormonal symptoms, who has an elevated serum PP or CgA level or a positive OctreoScan (Mallinckrodt Medical, Inc., St. Louis, MO) (somatostatin receptor scintigraphy [SRS]) (discussed in the next section). It is important to remember that an elevated PP level or CgA level is not specific for NF-PNETs.<sup>29,31,32,63,100</sup>

## MISCELLANEOUS PANCREATIC NETS

For VIPomas, glucagonomas, somatostatinomas, and PPomas, the biochemical markers are VIP, glucagon, somatostatin, and PP, respectively.<sup>1</sup> For every PNET, always screen for MEN type I syndrome measuring ionized calcium, serum PTH, and prolactin.<sup>102</sup> Biochemical screening for PNETs, in the presence of suspected MEN I syndrome, can include gastrin, insulin/proinsulin, PP, glucagon, and CgA, together having a sensitivity of approximately 70%, which can be increased if  $\alpha$ -hCG and  $\beta$ -hCG subunits, VIP, and postprandial gastrin and PP measurements are added.<sup>13</sup>

## Acromegaly or Gigantism

Acromegaly or gigantism can present when any NET secretes GH or GH-releasing hormone (GHRH). Basal levels of GH and IGF-1 are usually enough to make a diagnosis; but in 15% to 20% of the patients, further investigation is needed to show nonsuppressibility of GH to an oral glucose tolerance test, a somatostatin inhibition test, or a bromocriptine suppression test. In the case of the oral glucose tolerance test, also measure lipids and insulin, which should also be suppressed. Other pituitary and hypothalamic hormones should also be measured, such as prolactin, the  $\alpha$  and  $\beta$  subunits of gonadotropins, and thyroid-stimulating hormone.<sup>4</sup>

## Cushing Syndrome

A pituitary tumor, small cell carcinoma of the lung (known to produce ACTH), or an ACTH-secreting NET will present clinically as Cushing syndrome from oversecretion of cortisol, adrenal androgens, and 11-deoxycorticosterone. To reach the diagnosis, several steps should be followed. New guidelines for the diagnosis of Cushing syndrome have been published, although some of the recommendations are based on low-quality evidence. Their proposed approach is as follows.

After excluding exogenous glucocorticoid use (iatrogenic Cushing syndrome), patients with unusual features for age such as osteoporosis or hypertension, patients with multiple and progressive features predictive of Cushing syndrome (easy bruising, facial plethora, proximal myopathy or muscle weakness, reddish/purple striae, weight gain in children with decreasing growth velocity),

and patients with adrenal incidentaloma compatible with adenoma should undergo testing for Cushing syndrome starting with 1 test with high diagnostic accuracy: urine free cortisol (at least 2 measurements), late night salivary cortisol (2 measurements), 1 mg overnight dexamethasone suppression test, or longer low-dose dexamethasone suppression test (2 mg/d for 48 hours). If the test is negative, and the pretest probability was low, then follow-up in 6 months is recommended for progression of symptoms; in case of a negative test but with a high pretest probability, more than 1 test should be performed. In some cases, a serum midnight cortisol or dexamethasone-corticotropin releasing hormone test should be done.<sup>103</sup>

## BIOCHEMICAL ASSESSMENT AND MONITORING FOR PNETS

Specific hormonal assays are needed to establish the diagnosis of each functional PET as outlined in the discussion of each tumor type in Pancreatic NETs. Specifically, for insulinomas, an assessment of plasma insulin, proinsulin, and C-peptide is needed at the time of glucose determinations, usually during a fast.<sup>29,37,104</sup> For ZES, serum gastrin is needed either alone or during a secretin provocation test.<sup>29,37,43,45,104</sup> For VIPomas, a plasma VIP level is needed; for glucagonoma, plasma glucagon levels; for GRFomas, plasma GH and GRF levels; for Cushing syndrome, urinary cortisol, plasma ACTH, and appropriate ACTH suppression studies; for hypercalcemia with PET, both serum PTH levels and PTH-rP levels are indicated; and for a PET with carcinoid syndrome, urinary 5-HIAA should be measured.<sup>29,33,63,104,105</sup> Plasma CgA can be used as a marker in patients with both functional and nonfunctional pancreatic endocrine tumors.<sup>29,104–106</sup> Chromogranin A should be used with caution as a marker of disease activity in patients treated with somatostatin analogs, because these agents significantly reduce plasma CgA levels, a change that may be more reflective of changes in hormonal synthesis and release from tumor cells than an actual reduction in tumor mass.<sup>17,105</sup> In patients on stable doses of somatostatin analogs, consistent increases in plasma CgA levels over time may reflect loss of secretory control and/or tumor growth.<sup>18,40,104–106</sup>

## PHEOCHROMOCYTOMAS

The main signs and symptoms of catecholamine excess include hypertension, palpitations, headache, sweating, and pallor. Less common signs and symptoms are fatigue, nausea, weight loss, constipation, flushing, and fever. According to the degree of catecholamine excess, patients may present with myocardial infarction, arrhythmia, stroke, or other vascular manifestations (eg, any organ ischemia). Similar signs and symptoms are produced by numerous other clinical conditions, and therefore, pheochromocytoma is often referred to as the “great mimic.”

In general, about 80% of pheochromocytomas are located in the adrenal medulla.<sup>107</sup> Extra-adrenal sympathetic paragangliomas in the abdomen most commonly arise from chromaffin tissue around the inferior mesenteric artery (the organ of Zuckerkandl) and aortic bifurcation, less commonly from any other chromaffin tissue in the abdomen, pelvis, and thorax.<sup>108</sup> Extra-adrenal parasympathetic paragangliomas are most commonly found in the neck and head.

Pheochromocytomas and sympathetic extra-adrenal paragangliomas almost all produce, store, metabolize, and secrete catecholamines or their metabolites. Head and neck paragangliomas, however, rarely produce significant amounts of catecholamines (<5%).

## EPIDEMIOLOGY

Pheochromocytomas and paragangliomas are rare and occur in about 0.05% to 0.1% of patients with sustained hypertension. However, this probably accounts for only 50% of people harboring pheochromocytoma or paraganglioma because about half the patients with pheochromocytoma or paraganglioma have paroxysmal hypertension or normotension. The prevalence of pheochromocytoma and paraganglioma can be estimated to lie between 1:6500 and 1:2500, with the annual incidence in the United States of 500 to 1600 cases per year.

## PATHOLOGY AND MOLECULAR GENETICS

Malignancy is defined by the presence of metastases. At present, it is estimated that at least 24% to 27% of pheochromocytomas or paragangliomas are associated with known genetic mutations; in children, this prevalence may be as high as 40%.<sup>109–114</sup>

Pheochromocytomas may occur sporadically or as part of hereditary syndrome. According to the latest studies, among patients with nonsyndromic pheochromocytoma, up to about 24% of tumors may be hereditary.<sup>109,114,115</sup> Hereditary pheochromocytoma is associated with MEN IIA or MEN IIB, NF-1, von Hippel-Lindau (VHL) syndrome, and familial paragangliomas and pheochromocytomas due to germ-line mutations of genes encoding succinate dehydrogenase subunits B, C, and D (SDHB, SDHC, and SDHD). In general, the traits are inherited in an autosomal dominant pattern.<sup>115</sup>

Specifically, MEN I- and NF-1-related pheochromocytoma always secrete epinephrine, VHL-related pheochromocytomas always secrete norepinephrine, and elevation of dopamine together with norepinephrine is seen in some SDHB-related paragangliomas. In contrast to MEN II, VHL, and NF-1 tumors that are almost always found in the adrenal gland, SDHB-related tumors are found in extra-adrenal localizations. In those patients with malignant disease secondary to an extra-adrenal paraganglioma, almost 50% had SDHB mutations.<sup>116</sup> Some studies suggested that more than two thirds of patients with SDHB-related pheochromocytoma or paraganglioma will develop metastatic disease.<sup>117,118</sup> Family history is often helpful in MEN II, VHL, and NF-1 tumors, but only 10% of the currently investigated patients with SDHB mutations have a positive family history for pheochromocytoma or paraganglioma.<sup>117</sup>

## BIOCHEMICAL MARKERS FOR PHEOCHROMOCYTOMAS AND PARAGANGLIOMAS

In line with these concepts, numerous independent studies have now confirmed that measurements of fractionated metanephrines (ie, normetanephrine and metanephrine measured separately) in urine or plasma provide superior diagnostic sensitivity over measurement of the parent catecholamines (Table 3).<sup>119–121</sup> However, to preserve high diagnostic sensitivity, it is strongly recommended to obtain blood samples in the supine position.<sup>122</sup>

Current recommendations are that initial testing for pheochromocytoma or paraganglioma must include measurements of fractionated metanephrines in plasma, urine, or both, as available.<sup>123</sup> Blood sampling should be performed at a supine position after about 15 to 20 minutes of intravenous catheter insertion. Food, caffeinated beverages, strenuous physical activity, or smoking are not permitted at least about 8 to 12 hours before the testing. The elevation of plasma metanephrines of more than 4-fold above the upper reference limit is associated with close to 100% probability of the tumor.<sup>124</sup>

Should additional biochemical testing be necessary, the possibility of false-positive results due to medications, clinical conditions (as described above), or inadequate sampling conditions (eg, blood sampling while seated) should first be considered and eliminated.<sup>124</sup> In patients with plasma metanephrine values above the upper reference limit and less than 4-fold above that limit, the clonidine suppression test combined with measurements of plasma catecholamines and normetanephrine may prove useful.<sup>124</sup> Guller et al<sup>125</sup> published in 2006 that the tests of choice to establish the diagnosis of pheochromocytomas are urinary normetanephrine and platelet norepinephrine with sensitivities of 96.9 and 93.8%, respectively. In a study conducted in Switzerland by Giovanella et al<sup>126</sup> in 2006, plasma metanephrines and CgA showed 95% sensitivity with comparable high specificity and diagnostic accuracy (96% and 96% for CgA, 94% and 95% for MN, respectively). If both were used, then sensitivity increased to 100%. The difference found between these 2 markers is that only CgA was correlated with tumor mass. In 2008, Bilek et al<sup>127</sup> also studied the use of CgA for pheochromocytoma and found that it is a great marker for following response to treatment and that the levels of CgA were correlated with the size and the malignancy of the tumor.

Paragangliomas are NETs that arise from the paravertebral axis. Sympathetic paragangliomas usually hypersecrete catecholamines and are localized in the thorax, abdomen, or pelvis. Parasympathetic paragangliomas are nonsecretory tumors usually localized in the head and neck area.<sup>128</sup>

Diagnosis of paragangliomas is similar to that of pheochromocytomas because these 2 entities differ only in their place of origin, extra-adrenal versus adrenal, respectively. Algeciras-Schimmich et al<sup>129</sup> suggested that when plasma fractionated metanephrines are measured and values are not 4-fold above upper normal limit, then serum or plasma CgA and urine fractionated metanephrines should be measured to confirm the diagnosis. After surgery, the biochemical follow-up should be done 1 to 2 weeks later with 24-hour urine fractionated catecholamines and metanephrines; if normal, complete resection is claimed, but if it persists elevated, a second primary or occult metastasis should be suspected and investigated. Young<sup>130</sup> also proposed an annual biochemical testing follow-up for life, with 24-hour urinary excretion of fractionated catecholamines and metanephrines or plasma fractionated metanephrines, and only in the case of elevated levels that imaging follow-up is considered.

All patients with paragangliomas should be considered for genetic testing with VHL, RET, NF1, SDHD, SDHB, and SDHC genes.<sup>128</sup> If positive, then first-degree relatives genetic testing should be suggested, and genetic counseling should be offered. First-degree relatives should always undergo biochemical testing with 24-hour urine fractionated metanephrines and catecholamines.<sup>130</sup>

## Medullary Carcinoma of the Thyroid

These originate from the parafollicular cells of the thyroid, which secrete calcitonin. They represent 4% to 10% of all thyroid neoplasms.<sup>131</sup> Medullary carcinoma of the thyroid can present as 2 different forms, sporadic (75%) or inherited (25%), and the last can be either isolated or part of the MEN II syndrome.<sup>132</sup> A germ-line autosomal dominant mutation in the RET protooncogene, which encodes for a transmembrane tyrosine kinase receptor, predisposes individuals to develop MCT. Screening for RET germ-line mutations has allowed for early and accurate diagnosis of patients at risk of developing MCT.<sup>133,134</sup>

The most common clinical presentation of MCT is a thyroid nodule, either single or as multinodular goiter. Usually, no other manifestations are present unless the tumor is already in

stage IV (metastatic disease), when diarrhea and/or flushing can present.<sup>135</sup>

The calcitonin secreting nature of these tumors and the fact that calcitonin is almost exclusively secreted by C cells explain why this hormone is the preferred biochemical marker for the diagnosis and follow-up of this disease; besides, it has been shown that calcitonin measurement is more sensitive than fine-needle aspiration for the diagnosis of MCT.<sup>135</sup> A 10-year survival of only 50% for MTC patients is reported in several series. The only possible means to improve the cure and survival rate of these patients consists in early diagnosis and early surgical treatment, while the MTC is still intrathyroid.<sup>135</sup> Costante et al<sup>131</sup> reported on 2007 that the positive predictive value of basal calcitonin levels greater than 100 pg/mL is 100% for MCT, and if PG stimulation test is used, calcitonin levels greater than 100 pg/mL had a positive predictive value of 40%, but below this cutoff value, the false-positive results increase until the positive predictive value of basal calcitonin levels greater than 20 pg/mL is less than 25%. Cohen et al<sup>132</sup> found that calcitonin levels are not only useful as diagnostic marker, but are also correlated with tumor size and metastasis, which gives some prognostic value to this hormone. When levels are less than 50 pg/mL preoperatively, the normalization of calcitonin levels postoperatively is found in 97.8% of the patients. Scheuba et al<sup>136</sup> recently published that values of basal calcitonin greater than 64 pg/mL or stimulated calcitonin levels greater than 560 pg/mL had a sensitivity of 100% for MCT. Calcitonin increase can be observed also in parafollicular C-cell hyperplasia (CCH) and other extrathyroidal conditions. The PG test is used to distinguish MCT from CCH because it is thought that the response to this stimulus is typical of pathological thyroid C cells. The cutoff value of calcitonin response between patients with MTC and CCH remains to be established.<sup>137</sup> Pentagastrin stimulation test is no longer available in the United States, but it consisted of the intravenous injection of 0.5 µg PG/kg body weight and measurements of calcitonin at 0, 1, 2, 5, and 10 minutes after the injection; healthy people do not experience an increase in calcitonin greater than 200 pg/mL after the administration of PG.<sup>4</sup> Instead, calcitonin provocation can also be accomplished with an intravenous calcium infusion; however, there is a significant danger of cardiac arrhythmias.

### C-Cell Hyperplasia

This entity has been proposed to be a precancerous lesion that eventually transforms into MCT. Schley et al<sup>138</sup> submitted a study where 3 cases are reported in which patients presented with flushing, abdominal pain, diarrhea, and facial telangiectasia, resembling carcinoid syndrome, but the only biochemical abnormalities were elevated calcitonin levels and positive PG and calcium infusion tests. Venous sampling was performed, and it localized the overproduction of calcitonin to the thyroid, and histology showed CCH. After thyroidectomy, symptoms resolved and calcitonin levels returned to normal. They proposed that the condition might be a gene mutation, but so far, the site has not been identified considering that RET protooncogene was negative in the 3 patients. These findings suggest that every case of flushing and diarrhea should have a calcitonin measurement, considering CCH or MCT in the differential diagnosis.

### Multiple Endocrine Neoplasia Syndromes

This entity is classified as MEN either type I or II. They are both inherited in an autosomal dominant pattern. Mutations on the MEN I tumor suppressor gene (inactivated) or the RET protooncogene (activated) are found in MEN types I and II, respectively.<sup>139</sup>

### MEN Type I

Multiple endocrine neoplasia type I is characterized by hyperplasia and/or neoplasm of the parathyroid glands, enteropancreatic neuroendocrine tumors (PNETs), and pituitary adenomas. Some patients do not present with all these tumors, so it has been agreed that diagnosis is made when a patient presents with 2 of these concomitantly. To diagnose familial MEN I syndrome, a first-degree relative has to present at least 1 of the tumors mentioned above.<sup>140</sup> Hyperparathyroidism occurs in about 90% of patients; endocrine pancreatic tumors in 60% of patients. Usually they are small and nonfunctional; the most common hormonally active ones are insulinomas or gastrinomas. Pituitary adenomas are present in 40% of patients, and in 60% of the patients, skin manifestations can also be present.<sup>140,141</sup> Genetic studies are available for MEN type I syndrome; MEN I germ-line mutations are found in these patients, but its presence does not prompt any immediate intervention.<sup>142</sup> Piecha et al<sup>140</sup> proposed a recommendation for carriers of MEN I mutation to be screened biochemically every 1 to 3 years for hyperparathyroidism, prolactinoma, gastrinoma, insulinoma, and other enteropancreatic tumors.

### MEN Type II

This syndrome is subclassified into type IIA, IIB, and familial MCT, all sharing the presence of MCT; and they are all characterized by an activating germ-line mutation in the RET protooncogene, specific for each type and which can be identified in almost 100% of the patients, with genetic testing. Once the genetic test demonstrates the mutation, a total thyroidectomy is mandatory either prophylactically in carriers or as treatment in patients who already present with manifestations of the syndrome.<sup>143</sup> Multiple endocrine neoplasia type IIA presents with MCT, bilateral pheochromocytomas, and primary hyperparathyroidism; lately, it has been published that Hirschsprung disease could also be a manifestation of this syndrome, and genetic screening for RET protooncogene mutation is recommended in this patients<sup>144</sup>; MEN type IIB is an association of MCT, pheochromocytomas, and mucosal neuromas<sup>145</sup>; these patients usually present with a marfanoid phenotype.

The biochemical studies recommended for these syndromes are the same as previously proposed for each tumor type, depending on the clinical syndrome, and in the case when MEN syndrome is suspected, genetic testing should also be performed in the patient and if positive first-degree relatives should also be tested.

## CLASSIFICATION OF THE BIOCHEMICAL MARKERS ACCORDING TO THEIR USE (TABLE 4)

### Diagnostic

#### Chromogranins A and B

Both are part of the granin family. They are stored and secreted from vesicles present in the neuroendocrine cells, together with other peptides, amines, and neurotransmitters.<sup>146</sup> Chromogranin A is the best studied<sup>147</sup> and most used, but CgA is not perfect. Stridsberg et al<sup>148</sup> reported there are some common conditions that can increase the levels of this marker and give false-positive measurements including decreased renal function and treatment with PPIs and even essential hypertension<sup>149</sup>; these problems are not seen with CgB, so they proposed measurement of CgB as a complement to CgA.<sup>148</sup>

The most important characteristic of these markers is that they are secreted not only by the functional tumors, but also by those less well-differentiated NETs that do not secrete known hormones.<sup>2</sup>

High CgA has been shown to be increased in 50% to 100% of patients with NETs.<sup>150</sup> Chromogranin A levels may be associated with the primary tumor (gastrinomas 100%, pheochromocytomas 89%, carcinoid tumors 80%, nonfunctioning tumors of the endocrine pancreas 69%, and medullary thyroid carcinomas 50%). In addition, blood levels depend upon tumor mass, tumor burden, or progression and malignant nature of the tumor.<sup>127,151</sup> Small tumors may be associated with normal CgA levels.

Sensitivity and specificity of CgA depend on many factors. For example, sensitivity varies from 77.8% to 84% and specificity from 71.3% to 85.3%, depending on the assay used, and of great importance is to establish the cutoff value that gives the highest sensitivity without compromising the specificity.<sup>152</sup> Another utility of CgA is to discriminate between patients with or without metastasis, which also depends on the assay and the cutoff values used, with a sensitivity of 57% to 63.3% and specificity 55.6% to 71.4%.<sup>152</sup>

### Pancreatic Polypeptide

Pancreatic polypeptide is considered another nonspecific biochemical marker. In a study conducted by Panzuto et al<sup>153</sup> in Rome, Italy, in 2004, PP sensitivity was 54% in functioning tumors, 57% in nonfunctioning, 63% in pancreatic tumors, and 53% in GI tumors. Specificity was 81% compared with disease-free patients, and 67% compared with nonendocrine tumors' patients. But when combined with CgA, the sensitivity increased compared with either of the markers alone. When used in combination, the sensitivity of these markers is 96% for gastroentero-PNETs; for nonfunctioning tumors, 95%; and for pancreatic tumors, 94%.<sup>153</sup>

### Neuron-Specific Enolase

Neuron-specific enolases are enzymes that occur mainly in cells of neuronal and neuroectodermal origin. Neuron-specific

enolase has been found in thyroid and prostatic carcinomas, neuroblastomas, small cell lung carcinoma, carcinoids, gastroentero-PNETs, and pheochromocytomas. Despite its high sensitivity (100%), its use is limited as a blood biochemical marker for NETs because of its very low specificity (32.9%).<sup>26</sup>

## DETERMINING PROGNOSIS

### Chromogranin A

Other than the applications of CgA previously discussed, this marker can be used for prognosis and follow-up. Jensen et al<sup>154</sup> found that a reduction on CgA levels of 80% or greater after cytoreductive surgery for carcinoid tumors predicts symptom relief and disease control; it is associated with improved patient outcomes, even after incomplete cytoreduction.

### Pancreastatin

One of the posttranslational processing products of CgA has found to be an indicator of poor outcome when its concentration in plasma is elevated before treatment in patients with NETs. A level of greater than 500 pmol/L is an independent indicator of poor outcome. This marker is also known to correlate with the number of liver metastasis, so it would be appropriate to use it in the follow-up of NET patients. Furthermore, Stronge et al<sup>155</sup> found that an increase in pancreastatin levels after somatostatin-analog therapy is associated with a poor survival. Other studies have shown that pancreastatin should be measured before treatment and monitored during and after it. Plasma levels of this marker greater than 5000 pg/mL before treatment were associated with increased perioperative mortality in patients with NETs that underwent hepatic artery chemoembolization.<sup>156</sup>

These observations suggest that pancreastatin is potentially a very useful marker not only for diagnosis but more importantly also for monitoring treatment response.

**TABLE 4.** Specific Biochemical Markers for Each Tumor Type<sup>211</sup>

Site	Tumor Type	Marker	Specificity
All		CgA and CgB	High
		PP, NSE, neurokinin, Neurotensin	Intermediate
		HCG $\alpha$ and $\beta$	Low
Thymus	Foregut Carcinoid	ACTH	Intermediate
Bronchus	Foregut carcinoid, small cell lung carcinoma	ACTH, ADH, Serotonin, 5-HIAA,	Intermediate
		Histamine, GRP, GHRH, VIP, PTH-rP	Low
Stomach	Foregut carcinoid, gastrinoma, ghrelinoma	Histamine, gastrin	Intermediate
		Ghrelin	Low
Pancreas	Gastrinoma, insulinoma, glucagonoma, somatostatinoma, PPoma, VIPoma	Gastrin, insulin, proinsulin, glucagon, somatostatin	High
		C-peptide, neurotensin, VIP, PTH-rP, calcitonin	Low
Duodenum	Gastrinoma, somatostatinoma.	Somatostatin, gastrin	High
Ileum	Midgut carcinoid	Serotonin, 5-HIAA	High
		Neurokinin A, neuropeptide K, substance P	Intermediate
Colon and rectum	Hindgut carcinoid	Peptide YY, somatostatin	Intermediate
Bone	Metastasis	Bone alkaline phosphatase, <i>N</i> -telopeptide	High (blastic lesions), modest (lytic lesions)
		PTH-rP	Intermediate
		BNP	Intermediate
Cardiac involvement	Carcinoid	BNP	Intermediate

This table shows the specific biochemical markers used for each tumor and their specificity.

CgA and CgB indicates chromogranins A and B; HCG, human chorionic gonadotropin; ACTH, adrenocorticotropic hormone; ADH, anti diuretic hormone; 5-HIAA, GRP, gastrin-releasing peptide; BNP, brain natriuretic peptide.

### Neurokinin A

Neurokinin A has been shown to have a strong prognostic value. Turner et al<sup>157</sup> in 2006 showed that in patients with midgut carcinoid that have raised plasma NKA, a reduction of this biochemical marker after somatostatin analog therapy was associated with an 87% survival at 1 year compared with 40% if it increased. They also concluded that any alteration in NKA predicts improved or worsening survival.<sup>157</sup>

### DIAGNOSIS OF BONE METASTASIS

Metastases from NETs can be either lytic and/or osteoblastic (Table 4). There may be an increased osteoclast activity contributing to lytic lesions and or an increased osteoblastic activity responsible for blastic metastases. Bone markers in lytic and osteoblastic metastases that may assist in the evaluation of stage as well as response to therapy include bone alkaline phosphatase, an indicator of osteoblast function, and urinary *N*-telopeptide, which reflects osteoclast activity or bone resorption. Somewhat paradoxically, only blastic metastases show an increase in both markers.<sup>158</sup>

Increased osteoclast activity predicts a poor outcome, with a relative risk (RR) for high *N*-telopeptide (>100 nmol BCE/mM

creatinine) of skeletal-related events, RR = 3.3 ( $P < 0.001$ ); disease progression, RR = 2.0 ( $P < 0.001$ ); and death, RR = 4.6 ( $P < 0.001$ ).<sup>159</sup>

### BIOCHEMICAL DIAGNOSIS OF CARDIAC INVOLVEMENT

Carcinoid heart disease is a unique cardiac disease associated with NETs and may be seen in up to 60% of patients with metastatic carcinoid. Valvular disease is the most common pathological feature, and tricuspid damage is found in 97% and pulmonary valve disease in 88%, with 88% displaying insufficiency and 49% showing stenosis. The distinctive carcinoid lesion consists of deposits of fibrous tissue devoid of elastic fibers known as carcinoid plaque. The deposits are found on the endocardial surface on the ventricular aspect of the tricuspid leaflet and on the arterial aspect of the pulmonary valve cusps.<sup>160</sup>

Although the precise cause for the plaque formation is not entirely clear, the direct actions of 5-HT and bradykinin have been implicated in animal studies. This finding is corroborated by the observation that the appetite-suppressant drug fenfluramine, which releases 5-HT, has been noted to cause valvular distortion similar to that seen in carcinoid heart disease.<sup>158</sup> Values of 5-HT greater than 1000 ng/mL seem to consort with the development of carcinoid heart disease.

Pro-brain natriuretic peptide can be used as a biomarker for the detection of carcinoid heart disease with high specificity and sensitivity and used as an adjunct to deciding who requires echocardiography.<sup>159</sup>

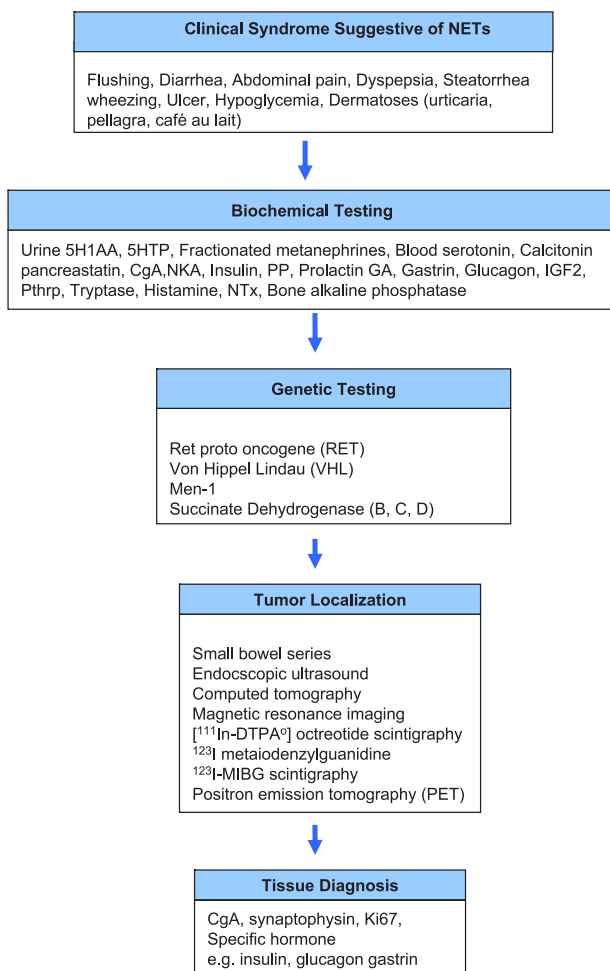
### INITIAL IMAGING OF THE PATIENT WITH A SUSPECTED NET

#### Imaging of Gastric Carcinoid Tumors

Most gastric carcinoid tumors are directly imaged and diagnosed during endoscopy. For larger lesions, endoscopic ultrasound (EUS) may be performed to assess whether the gastric carcinoid is invasive. This technique, when used with tattooing of the gastric lesion, offers the endoscopist the opportunity to observe the lesion in a serial fashion. This is highly valuable in the case of type I gastric carcinoids, which rarely need a formal gastric resection. In patients with more aggressive gastric carcinoids such as type 2 gastric carcinoids, EUS offers the endoscopist the opportunity to access nearby nodes as well as the depth of tumor invasion. Cross-sectional imaging with CT or MRI is recommended to assess for metastases in patients with type I or type II gastric carcinoids more than 2 cm in diameter, or for patients with type 3 gastric carcinoids in whom metastatic risk is a concern.<sup>16</sup> The predominant site of distant metastatic spread in patients with gastric carcinoid tumors is the liver. Carcinoid liver metastases are often hypervascular and may become isodense relative to the liver with the administration of intravenous contrast. Computed tomography scans should thus be performed both before and after the administration of intravenous contrast agents.<sup>163</sup> Somatostatin receptor scintigraphy provides a second useful imaging modality for the detection of metastatic disease in patients with malignant gastric carcinoids.<sup>16,163,164</sup>

#### Imaging of Midgut NETs

Imaging studies for NETs are generally done for initial staging and subsequent follow-up. Goals for initial staging include identification of primary tumor, assessment of extent of disease, and treatment planning. Subsequent follow-up imaging studies are done for surveillance after complete resection or during periods of stability and evaluation of response after



**FIGURE 1.** Algorithm for diagnosis of NETs.<sup>70–72</sup> Based on the clinical presentations, specific measures are selected for evaluation of each patient. NTx indicates *N*-telopeptide.

treatment. Imaging modalities commonly used include the following:

- small-bowel series
- computed tomography (CT)
- MRI
- [<sup>111</sup>In-DTPA<sup>0</sup>] octreotide scintigraphy
- [<sup>123</sup>I] meta-iodobenzylguanidine (<sup>123</sup>I MIBG) scintigraphy
- positron emission tomography (PET)

### Initial Staging of Midgut NETs

Imaging studies generally recommended at time of initial staging includes plain film of the chest, cross-sectional imaging (CT or MRI) of the abdomen and pelvis, and [<sup>111</sup>In-DTPA<sup>0</sup>] octreotide scintigraphy. In cases, where a midgut primary is suspected but not directly identified (eg, a mesenteric mass in the ileal mesentery), often small-bowel series or multiphasic CT of the abdomen and pelvis with thin section and negative bowel contrast can be used to locate the primary tumor.

### Techniques for Cross-Sectional Imaging

Neuroendocrine tumors are generally vascular tumors that enhance intensely with intravenous contrast during early arterial phases of imaging with washout during the delayed portal venous phase. The key to detecting small NETs on CT is to maximize the contrast between the tumor and the adjacent normal parenchyma. For abdominal and pelvic imaging, we recommend multiphasic CT that includes the arterial phase (beginning 25–30 seconds after the start of contrast injection) and the portal venous phase (beginning approximately 60 seconds after the start of contrast injection). Rapid intravenous bolus of contrast at 4 to 5 mL/s is also recommended. Thin sectioning and the use of a negative oral contrast agent also may be helpful in detecting small primary tumor in the small-bowel that may not otherwise be seen.

Magnetic resonance imaging (MRI) is preferred over CT for patients with a history of allergy to iodine contrast material or for those with renal insufficiency. Neuroendocrine tumors can have variable appearances on noncontrast MRI. They can be hypointense or isointense on T1-weighted images. Metastases to the liver typically are usually high signal on T2-weighted images.<sup>165</sup> Because T2-weighted images are obtained without intravenous contrast, they do not have the problems of variations in the timing of phases of contrast enhancement. T2-weighted imaging can be especially useful for patients unable to receive contrast. However, these metastases, especially when cystic or necrotic, can mimic the appearance of other T2 high-signal-intensity lesions, such as hemangiomas and, occasionally, cysts.<sup>166</sup> Dynamic contrast-enhanced imaging can provide additional information about the nature of the lesions and help to detect smaller lesions. We recommend T1-weighted, T2-weighted imaging, and multiphasic (arterial, portal venous, and delayed) dynamic MRI for NETs.<sup>165,167</sup>

Some have reported that MRI may be more sensitive than CT is for the detection of small liver metastases.<sup>168,169</sup> However, CT may be better for the evaluation of peritoneal and mesenteric disease. It is likely whether CT or MRI is better overall for NETs will continue to be debated and may vary depending on the expertise of the local center.

### Nuclear Imaging of NETs

<sup>111</sup>In-labeled somatostatin analog [<sup>111</sup>In-DTPA<sup>0</sup>] octreotide was developed for scintigraphy of NETs. It shares the receptor-binding profile of octreotide, which makes it a good radiopharmaceutical for imaging of somatostatin receptors 2 and 5–positive tumors.<sup>170</sup> The overall sensitivity of [<sup>111</sup>In-DTPA<sup>0</sup>] octreotide scintigraphy seems to be about 80% to 90%.<sup>170</sup> Unlike cross-

sectional imaging, which are generally site directed, [<sup>111</sup>In-DTPA<sup>0</sup>] octreotide scintigraphy is generally done as whole-body imaging and thus can detect disease at unsuspected sites.

Imaging is generally performed at 4 to 6 hours and at 24 hours. Imaging at 24 hours provides better contrast because of lower background activity. However, there is often physiological bowel activity that may produce false-positive results. At 4 to 6 hours, some lesions may be obscured by relatively high background activity; however, bowel activity is limited. Single photon emission tomography imaging with Ct coregistration may be helpful in resolving the nature of indeterminate lesions found on CT and enhance the sensitivity and specificity study.

[<sup>111</sup>In-DTPA<sup>0</sup>] Octreotide scintigraphy can be performed for patients on long-acting octreotide but is best performed at end of the dosing interval (3–6 weeks after the last dose). Although [<sup>111</sup>In-DTPA<sup>0</sup>] octreotide scintigraphy can provide useful information about the site of disease, it does not give information about the size. Some agents such as interferon may upregulate somatostatin receptors and thus can lead to increased uptake without disease progression.

Positron emission tomography ([<sup>18</sup>F]-fluorodeoxyglucose (FDG) imaging, although successful for many solid tumors, has not been helpful for NETs because of their generally lower proliferative activity. Prior studies have shown <sup>11</sup>C-5-HTP PET to be a promising imaging modality for the detection of NETs.<sup>170</sup> The 5-HT precursor 5-HTP labeled with <sup>11</sup>C was used and showed an increased uptake and irreversible trapping of this tracer in NETs.<sup>171</sup> [<sup>11</sup>C]-5-HTP PET proved better than SRS for tumor visualization. However, the short half-life of <sup>11</sup>C (*t*<sub>1/2</sub> = 20 minutes) makes it difficult to apply in clinical practice and is not available in the United States.

### Imaging of Pancreatic NETs

#### General

Imaging of the primary tumor location and the extent of the disease is needed for all phases of management of patients with PNETs. It is needed to determine whether surgical resection for possible cure or possible cytoreductive surgery is needed and whether treatment for advanced metastatic disease is appropriate and during follow-up to assess the effects of any antitumor treatment as well as the need for deciding whether additional treatments directed at the PNETs are indicated.<sup>29,63,172,173</sup> Functional PNETs (especially insulinomas, duodenal gastrinomas) are often small in size, and localization may be difficult.<sup>29,63,172,173</sup> A number of different imaging modalities have been widely used including conventional imaging studies (CT, MRI, ultrasound, angiography)<sup>163,174–176</sup> EUS<sup>29,177,178</sup> functional localizations studies measuring hormonal gradients<sup>29,179–181</sup>, intraoperative methods particularly intraoperative ultrasound<sup>29,182,183</sup>; and recently, the use of PET preoperatively.<sup>171,176,184,185</sup> A few important points in regard to each will be made in the following section.

#### Conventional Imaging Studies for PNETs Studies (CT, MRI, Ultrasound, Angiography)

Although PNETs are highly vascular tumors, and most of these studies are now performed with contrast agents, the results with conventional imaging studies are dependent to a large degree on the tumor size.<sup>29,163,172,186,187</sup> Although conventional imaging studies detect greater than 70% of PNETs that are more than 3 cm, they detect less than 50% of most PNETs that are less than 1 cm, therefore frequently missing small primary PNETs (especially insulinomas, duodenal gastrinomas) and small liver metastases.<sup>29,163,172,186,187</sup> At least 1 of these modalities is

generally available in most centers, with CT scanning with contrast being most frequently used as the first imaging modality.

### Somatostatin Receptor Scintigraphy

Pancreatic NETs, similar to carcinoid tumors, frequently (>80%, except insulinomas) overexpress somatostatin receptors (particularly subtypes sst 2, 5), which bind various synthetic analogs of somatostatin (octreotide, lanreotide) with high affinity.<sup>29,174–176,188</sup> A number of radiolabeled somatostatin analogs have been developed to take advantage of this finding to image PNETs, with the most widely used worldwide and the only one available in the United States being <sup>111</sup>In-DTPA-octreotide (OctreoScan).<sup>29,174–176,188</sup> Somatostatin receptor scintigraphy combined with CT detection (single photon emission CT) is more sensitive than conventional imaging for the detection of both the primary (except insulinomas) PET and metastatic PNETs to liver, bone, or other distant sites.<sup>59,174–176,188,189</sup> This sensitivity allows SRS to detect 50% to 70% of primary PNETs (less frequent with insulinomas or duodenal gastrinomas) and more than 90% of patients with metastatic disease.<sup>29,174–176,190,191</sup> It has the advantage of allowing total body scanning quickly at one time, and its use has resulted in a change in management of 24% to 47% of patients with PNETs.<sup>29,174–176,190,191</sup> False-positive localizations can occur in up to 12% of patients, so it is important to interpret the result within the clinical context of the patient, and by doing this, the false-positive rate can be reduced to 3%.<sup>29,175,191,192</sup>

### Endoscopic Ultrasound

Endoscopic ultrasound combined with fine-needle aspiration can be useful in distinguishing an NF-PET from adenocarcinoma or some other cause of a pancreatic mass.<sup>29,177,178</sup> Fine-needle aspiration is rarely used to diagnose functional PNETs because they are suggested by symptoms, and the diagnosis is established by hormonal assays.<sup>29,63</sup> Endoscopic ultrasound is much more effective for localizing intrapancreatic PNETs than extrapancreatic PNETs such as duodenal gastrinomas or somatostatinomas.<sup>29,63,177</sup> Endoscopic ultrasound is particularly helpful in localizing insulinomas, which are small, almost always intrapancreatic, and frequently missed by conventional imaging studies and SRS.<sup>29,63,177</sup> Endoscopic ultrasound can identify an intrapancreatic PET in about 90% of cases.<sup>29,177</sup> Endoscopic ultrasound can also play an important role in the management of patients with MEN I who contain NF-PNETs in 80% to 100% of cases or in patients with NF-PNETs with VHL syndrome, which occur in 10% to 17%, which are often small and whose management is controversial.<sup>29,34,40,193–195</sup> Endoscopic ultrasound can detect many of these small NF-PNETs, and it has been proposed that serial evaluations with EUS be used to select which MEN I or VHL patients should have surgery.<sup>29,34,40,194–196</sup> functional localization (assessing hormonal gradients), and PET scanning for PNETs.

Assessment of hormonal gradients is now rarely used except in occasional patients with insulinomas or gastrinomas not localized by other imaging methods.<sup>29,179–181,186,197</sup> When used, it is now usually performed at the time of angiography and combined with selective intra-arterial injections of calcium for primary insulinomas or secretin for a primary gastrinoma or possible metastatic gastrinoma in the liver with hepatic venous hormonal sampling.<sup>29,179–181,186,197</sup> Positron emission tomographic scanning for PNETs receiving increasing attention because of its increased sensitivity.<sup>29,171,184–186</sup> With PNETs, <sup>11</sup>C-5 hydroxytryptophan or <sup>68</sup>gallium-labeled somatostatin analogs have been shown to have greater sensitivity than SRS or conventional imaging studies and therefore may be clinically useful in the future. At present, neither of these methods is ap-

proved for use in the United States and is not available in the United States.<sup>29,171,176,184,185</sup>

### Intraoperative Localization of PNETs

During surgery, the routine use of intraoperative ultrasound is recommended especially for pancreatic PNETs,<sup>29,182,183</sup> and for small duodenal tumors (especially duodenal gastrinomas), endoscopic transillumination<sup>29,198,199</sup> in addition to routine duodenotomy is recommended.<sup>29,56,177,199–201</sup> These will be discussed in more detail in the surgical section below.

### Imaging for Pheochromocytomas and Paragangliomas

Either CT or MRI is recommended for initial tumor localization, with MRI preferred in children and pregnant or lactating women because of concerns regarding radiation exposure. Recent data suggest that adrenergic blockade in pheochromocytoma or paraganglioma patients as a specific precautionary measure before intravenous nonionic contrast-enhanced CT imaging is not necessary (unpublished observations). Computed tomography and MRI have excellent sensitivity for detecting most catecholamine-producing tumors; these anatomical imaging approaches lack the specificity required to unequivocally identify a mass as a pheochromocytoma or paraganglioma.<sup>202</sup> The specificity of functional imaging using <sup>123</sup>I MIBG scintigraphy offers an approach that overcomes the specificity limitations of anatomical imaging. Reduced sensitivity of MIBG scans in familial paraganglioma syndromes, malignant disease, and extra-adrenal paragangliomas has been described.<sup>203–206</sup> Newer compounds such as [<sup>18</sup>F]-fluorodopamine ([<sup>18</sup>F]-FDA), [<sup>18</sup>F]-fluorodihydroxyphenylalanine ([<sup>18</sup>F]-FDOPA), and [<sup>18</sup>F]-fluoro-2-deoxy-D-glucose ([<sup>18</sup>F]-FDG) have emerged for use in PET. The superiority of [<sup>18</sup>F]-FDA PET imaging over [<sup>123</sup>I]-MIBG scintigraphy, especially in malignant tumors, has been reported.<sup>204</sup> [<sup>18</sup>F]-FDOPA PET imaging has been described to outperform [<sup>123</sup>I]-MIBG scintigraphy in the detection of pheochromocytoma.<sup>208</sup> However, the sensitivity of [<sup>18</sup>F]-FDOPA for metastatic paragangliomas is limited.<sup>209</sup> Studies have revealed that most pheochromocytomas show uptake of [<sup>18</sup>F]-FDG in PET imaging.<sup>210,211</sup> Recently, [<sup>18</sup>F]-FDG was demonstrated to be a superior tool in the evaluation of metastatic SDHB-associated adult pheochromocytoma and paraganglioma.<sup>212</sup> It is recommended that functional imaging be used on all pheochromocytomas and paragangliomas, except adrenal pheochromocytomas, that are less than 5 cm in size and associated with elevations of plasma or urine metanephrine (practically all epinephrine-producing pheochromocytomas are found in the adrenal gland or are recurrences of previously resected adrenal tumors).

### Summary of Imaging for NETs

The preliminary workup of a NET often starts in the emergency department with plain abdominal x-rays done to work up an abdominal pain syndrome. Any abnormal finding leads to CT scanning, and the discovery of liver metastasis inevitably leads to CT-guided liver biopsy. These tests are often used nonspecific because of the presence of vague symptom complexes. Once the NET diagnosis is suspected, more specific means of imaging are typically used. For detecting the primary NET tumor, a multimodality approach is best and may include CT, MRI, SRS, EUS, endoscopy, and, less commonly, digital selective angiography or venous sampling. Computed tomography is probably superior for localizing the primary tumor, mesenteric invasion, and thoracic lesions, whereas gadolinium-enhanced MRI is superior in characterizing liver lesions. Technique is critical, and meticulous attention to detail is necessary;

multidetector-row CT and MRI gradients have enhanced diagnostic performance. Whereas some investigators in Europe advocate the use of enteroclysis with CT imaging, this technique is not readily available in most US hospitals and thus is rarely done here in the United States.

The most sensitive imaging modality for detecting widespread metastatic disease in NETs is SRS (In-111-labeled OctreoScan, Mallinckrodt Medical, Inc., St. Louis, MO). However, SRS is less sensitive for metastatic insulinomas because only 40% to 50% express type 2 somatostatin receptors (sst 2) needed for SRS. Recent findings using glucagon receptor<sup>213</sup> imaging suggest that this may replace OctreoScans when insulinomas have not been identified, but this has not been done in the United States. OctreoScans are extremely useful in confirming the diagnosis and evaluating tumor distribution and burden. The use of PET scanning in undifferentiated tumors or small cell-like lesions of the bronchus or thymus is highly effective. The role of PET scanning for well-differentiated NETs is less delineated. Only tumors with high proliferative activity and dedifferentiation show FDG-PET uptake. Positron emission tomography with tracers based on metabolic features (5 HTP) and receptor characteristics (DOTATOC) has shown promising results in a limited number of studies.

Once a gut-based NET is suspected, barium studies or endoscopy may rarely be helpful to localize the primary tumor. The use of capsule endoscopy and double-balloon push-pull enteroscopy has been useful in cases of midgut-based NETs. Endoscopic ultrasound combined with biopsy is the most sensitive method to detect PNETs.

Recently, <sup>123</sup>I MIBG scanning has been added to the diagnostic tools of US for the physician working up NETs. This scan offers information that is additive to the information gained by SRS imaging. In some patients, SRS scanning is negative in some lesions, and other lesions light up on MIBG scanning. In other patients, SRS imaging and MIBG scans both are positive or negative. In the case where both scans are positive, these patient may be candidates for future therapy with <sup>133</sup>I MIBG or peptide receptor radiotherapy with radiolabeled somatostatin analogs.<sup>214</sup>

## SUMMARY AND CONCLUSIONS

To conclude, this algorithm proposes a summary of the steps for the diagnosis of NETs starting at the presentation of a suggestive clinical scenario.<sup>102</sup>

Neuroendocrine tumors are small, slow-growing neoplasms, usually with episodic expression that makes diagnosis difficult, erroneous, and often late; for these reasons, a high index of suspicion is needed, and it is important to understand the pathophysiology of each tumor to decide which biochemical markers are more useful and when they should be used.

It is the purpose of this guideline to show the importance of recognizing, as early as possible, the clinical syndromes that suggest a NET as one of the differential diagnoses, and once suspected, look for the appropriate biochemical markers and radiological or other means that will confirm the diagnosis or confidently discard it. Ultimately, all 3 modalities are important to create a platform for monitoring response to therapy, determining prognosis, and choosing the right therapeutic intervention.

## REFERENCES

- Massironi S, Sciola V, Peracchi M, et al. Neuroendocrine tumors of the gastro-entero-pancreatic system. *World J Gastroenterol*. 2008;14:5377–5384.
- Eriksson B, Oberg K, Stridsberg M. Tumor markers in neuroendocrine tumors. *Digestion*. 2000;62(suppl 1):33–38.
- Lamberts SWJ, Hofland LJ, Nobels FRE. Neuroendocrine tumor markers. *Front Neuroendocrinol*. 2001;22:309–339.
- Vinik A, O'Dorisio T, Woltering E, et al. *Neuroendocrine Tumors: A Comprehensive Guide to Diagnosis and Management*. 1st ed. Interscience Institute; 2006.
- Vinik AI. Carcinoid syndrome. Diffuse hormonal systems and endocrine tumor syndromes. 2008.
- Feldman JM, O'Dorisio TM. Role of neuropeptides and serotonin in the diagnosis of carcinoid tumors. *Am J Med*. 1986;81:41–48.
- Ahlman H, Dalström A, Grönstad K, et al. The pentagastrin test in the diagnosis of the carcinoid syndrome. Blockade of gastrointestinal symptoms by ketanserin. *Ann Surg*. 1985;201:81–86.
- Kaplan EL, Jaffe BM, Peskin GW. A new provocative test for the diagnosis of the carcinoid syndrome. *Am J Surg*. 1972;123:173–179.
- Vinik AI, Gonin J, England BG, et al. Plasma substance-P in neuroendocrine tumors and idiopathic flushing: the value of pentagastrin stimulation tests and the effects of somatostatin analog. *J Clin Endocrinol Metab*. 1990;70:1702–1709.
- Conlon JM. The glucagon-like polypeptides—order out of chaos? *Diabetologia*. 1980;18:85–88.
- Cunningham JL, Janson ET, Agarwal S, et al. Tachykinins in endocrine tumors and the carcinoid syndrome. *Eur J Endocrinol*. 2008;159:275–282.
- Won JG, Tseng HS, Yang AH, et al. Clinical features and morphological characterization of 10 patients with noninsulinoma pancreatogenous hypoglycaemia syndrome (NIPHS). *Clin Endocrinol (Oxf)*. 2006;65:566–578.
- Kaltsas GA, Besser GM, Grossman AB. The diagnosis and medical management of advanced neuroendocrine tumors. *Endocr Rev*. 2004;25:458–511.
- Rindi G, Bordi C, Rappel S, et al. Gastric carcinoids and neuroendocrine carcinomas: pathogenesis, pathology, and behavior. *World J Surg*. 1996;20:168–172.
- Norton JA, Melcher ML, Gibril F, et al. Gastric carcinoid tumors in multiple endocrine neoplasia-1 patients with Zollinger-Ellison syndrome can be symptomatic, demonstrate aggressive growth, and require surgical treatment. *Surgery*. 2004;136:1267–1274.
- Ruszniewski P, Delle FG, Cadiot G, et al. Well-differentiated gastric tumors/carcinomas. *Neuroendocrinology*. 2006;84:158–164.
- Oberg K, Kvols L, Caplin M, et al. Consensus report on the use of somatostatin analogs for the management of neuroendocrine tumors of the gastroenteropancreatic system. *Ann Oncol*. 2004;15:966–973.
- Janson ET, Holmberg L, Stridsberg M, et al. Carcinoid tumors: analysis of prognostic factors and survival in 301 patients from a referral center. *Ann Oncol*. 1997;8:685–690.
- National Cancer Institute. Surveillance, Epidemiology, and End Results (SEER) Program. SEER\*Stat Database: SEER 17 Regs Nov 2006 sub (1973–2004), ed released April 2006, National Cancer Institute, DCCPS, Surveillance Research Program, Cancer Statistics Branch. 2006. National Cancer Institute. Available at: [www.seer.cancer.gov](http://www.seer.cancer.gov). Accessed May 27, 2010.
- Wang GG, Yao JC, Worah S, et al. Comparison of genetic alterations in neuroendocrine tumors: frequent loss of chromosome 18 in ileal carcinoid tumors. *Mod Pathol*. 2005;18:1079–1087.
- Kytola S, Hoog A, Nord B, et al. Comparative genomic hybridization identifies loss of 18q22-qter as an early and specific event in tumorigenesis of midgut carcinoids. *Am J Pathol*. 2001;158:1803–1808.
- Choi IS, Estecio MR, Nagano Y, et al. Hypomethylation of LINE-1 and Alu in well-differentiated neuroendocrine tumors (pancreatic endocrine tumors and carcinoid tumors). *Mod Pathol*. 2007;20:802–810.
- Goebel SU, Serrano J, Yu F, et al. Prospective study of the value of serum chromogranin A or serum gastrin levels in the assessment of the presence, extent, or growth of gastrinomas. *Cancer*. 1999;85:1470–1483.
- Bernini GP, Moretti A, Ferdeghini M, et al. A new human

- chromogranin 'A' immunoradiometric assay for the diagnosis of neuroendocrine tumours. *Br J Cancer*. 2001;84:636–642.
25. Nehar D, Lombard-Bohas C, Olivieri S, et al. Interest of chromogranin A for diagnosis and follow-up of endocrine tumours. *Clin Endocrinol (Oxf)*. 2004;60:644–652.
  26. Bajetta E, Ferrari L, Martinetti A, et al. Chromogranin A, neuron specific enolase, carcinoembryonic antigen, and hydroxyindole acetic acid evaluation in patients with neuroendocrine tumors. *Cancer*. 1999;86:858–865.
  27. Tormey WP, FitzGerald RJ. The clinical and laboratory correlates of an increased urinary 5-hydroxyindoleacetic acid. *Postgrad Med J*. 1995;71:542–545.
  28. Feldman JM, Lee EM. Serotonin content of foods: effect on urinary excretion of 5-hydroxyindoleacetic acid. *Am J Clin Nutr*. 1985;42:639–643.
  29. Metz DC, Jensen RT. Gastrointestinal neuroendocrine tumors: pancreatic endocrine tumors. *Gastroenterology*. 2008;135:1469–1492.
  30. Kloppel G, Anlauf M. Epidemiology, tumour biology and histopathological classification of neuroendocrine tumours of the tract. *Best Pract Res Clin Gastroenterol*. 2005;19:507–517.
  31. Oberg K, Eriksson B. Endocrine tumours of the pancreas. *Best Pract Res Clin Gastroenterol*. 2005;19:753–781.
  32. Falconi M, Plockinger U, Kwekkeboom DJ, et al. Well-differentiated pancreatic nonfunctioning tumors/carcinoma. *Neuroendocrinology*. 2006;84:196–211.
  33. O'Toole D, Salazar R, Falconi M, et al. Rare functioning pancreatic endocrine tumors. *Neuroendocrinology*. 2006;84:189–195.
  34. Jensen RT, Berna MJ, Bingham DB, et al. Inherited pancreatic endocrine tumor syndromes: advances in molecular pathogenesis, diagnosis, management, and controversies. *Cancer*. 2008;113:1807–1843.
  35. Gibril F, Schumann M, Pace A, et al. Multiple endocrine neoplasia type 1 and Zollinger-Ellison syndrome: a prospective study of 107 cases and comparison with 1009 cases from the literature. *Medicine (Baltimore)*. 2004;83:43–83.
  36. Grant CS. Insulinoma. *Best Pract Res Clin Gastroenterol*. 2005;19:783–798.
  37. de Herder WW, Niederle B, Scoazec JY, et al. Well-differentiated pancreatic tumor/carcinoma: insulinoma. *Neuroendocrinology*. 2006;84:183–188.
  38. Hirshberg B, Livi A, Bartlett DL, et al. Forty-eight-hour fast: the diagnostic test for insulinoma. *J Clin Endocrinol Metab*. 2000;85:3222–3226.
  39. Quinkler M, Strelow F, Pirlich M, et al. Assessment of suspected insulinoma by 48-hour fasting test: a retrospective monocentric study of 23 cases. *Horm Metab Res*. 2007;39:507–510.
  40. Kann PH, Balakina E, Ivan D, et al. Natural course of small, asymptomatic neuroendocrine pancreatic tumours in multiple endocrine neoplasia type 1: an endoscopic ultrasound imaging study. *Endocr Relat Cancer*. 2006;13:1195–1202.
  41. Roy PK, Venzon DJ, Shojamanesh H, et al. Zollinger-Ellison syndrome. Clinical presentation in 261 patients. *Medicine (Baltimore)*. 2000;79:379–411.
  42. Jensen RT, Niederle B, Mity E, et al. Gastrinoma (duodenal and pancreatic). *Neuroendocrinology*. 2006;84:173–182.
  43. Berna MJ, Hoffmann KM, Serrano J, et al. Serum gastrin in Zollinger-Ellison syndrome: I. Prospective study of fasting serum gastrin in 309 patients from the National Institutes of Health and comparison with 2229 cases from the literature. *Medicine (Baltimore)*. 2006;85:295–330.
  44. Gibril F, Jensen RT. Zollinger-Ellison syndrome revisited: diagnosis, biologic markers, associated inherited disorders, and acid hypersecretion. *Curr Gastroenterol Rep*. 2004;6:454–463.
  45. Berna MJ, Hoffmann KM, Long SH, et al. Serum gastrin in Zollinger-Ellison syndrome: II. Prospective study of gastrin provocative testing in 293 patients from the National Institutes of Health and comparison with 537 cases from the literature. evaluation of diagnostic criteria, proposal of new criteria, and correlations with clinical and tumoral features. *Medicine (Baltimore)*. 2006;85:331–364.
  46. Arnold R. Diagnosis and differential diagnosis of hypergastrinemia. *Wien Klin Wochenschr*. 2007;119:564–569.
  47. Corleto VD, Annibale B, Gibril F, et al. Does the widespread use of proton pump inhibitors mask, complicate and/or delay the diagnosis of Zollinger-Ellison syndrome? *Aliment Pharmacol Ther*. 2001;15:1555–1561.
  48. Agreus L, Storskrubb T, Aro P, et al. Clinical use of proton-pump inhibitors but not H2-blockers or antacid/alginate raises the serum levels of amidated gastrin-17, pepsinogen I and pepsinogen II in a random adult population. *Scand J Gastroenterol*. 2009;44:564–570.
  49. Jensen RT. Consequences of long-term proton pump blockade: insights from studies of patients with gastrinomas. *Basic Clin Pharmacol Toxicol*. 2006;98:4–19.
  50. Roy PK, Venzon DJ, Feigenbaum KM, et al. Gastric secretion in Zollinger-Ellison syndrome. Correlation with clinical expression, tumor extent and role in diagnosis—a prospective NIH study of 235 patients and a review of 984 cases in the literature. *Medicine (Baltimore)*. 2001;80:189–222.
  51. Goldman JA, Blanton WP, Hay DW, et al. False-positive secretin stimulation test for gastrinoma associated with the use of proton pump inhibitor therapy. *Clin Gastroenterol Hepatol*. 2009;7:600–602.
  52. Thom AK, Norton JA, Axiotis CA, et al. Location, incidence, and malignant potential of duodenal gastrinomas. *Surgery*. 1991;110:1086–1091.
  53. Jensen R, Gardner J. Gastrinoma. In: Go VLW, DiMaggio EP, Gardner JD, et al, eds. *The Pancreas: Biology, Pathobiology and Disease*. 2nd ed. New York: Raven Press Publishing Co; 1993:931–978.
  54. Thakker RV. Multiple endocrine neoplasia. *Horm Res*. 2001;56(suppl 1):67–72.
  55. Hoffmann KM, Furukawa M, Jensen RT. Duodenal neuroendocrine tumors: classification, functional syndromes, diagnosis and medical treatment. *Best Pract Res Clin Gastroenterol*. 2005;19:675–697.
  56. Norton JA, Fraker DL, Alexander HR, et al. Surgery to cure the Zollinger-Ellison syndrome. *N Engl J Med*. 1999;341:635–644.
  57. Weber HC, Venzon DJ, Lin JT, et al. Determinants of metastatic rate and survival in patients with Zollinger-Ellison syndrome: a prospective long-term study. *Gastroenterology*. 1995;108:1637–1649.
  58. Yu F, Venzon DJ, Serrano J, et al. Prospective study of the clinical course, prognostic factors, causes of death, and survival in patients with long-standing Zollinger-Ellison syndrome. *J Clin Oncol*. 1999;17:615–630.
  59. Gibril F, Doppman JL, Reynolds JC, et al. Bone metastases in patients with gastrinomas: a prospective study of bone scanning, somatostatin receptor scanning, and magnetic resonance image in their detection, frequency, location, and effect of their detection on management. *J Clin Oncol*. 1998;16:1040–1053.
  60. Jensen RT. Management of the Zollinger-Ellison syndrome in patients with multiple endocrine neoplasia type 1. *J Intern Med*. 1998;243:477–488.
  61. Norton JA, Cornelius MJ, Doppman JL, et al. Effect of parathyroidectomy in patients with hyperparathyroidism, Zollinger-Ellison syndrome, and multiple endocrine neoplasia type I: a prospective study. *Surgery*. 1987;102:958–966.
  62. Norton JA, Venzon DJ, Berna MJ, et al. Prospective study of surgery for primary hyperparathyroidism (HPT) in multiple endocrine neoplasia-type 1 and Zollinger-Ellison syndrome: long-term outcome of a more virulent form of HPT. *Ann Surg*. 2008;247:501–510.
  63. Jensen RT. Endocrine neoplasms of the pancreas. In: Yamada T, Alpers DH, Kalloo AN, et al, eds. *Textbook of Gastroenterology*. 5th ed. Oxford, England: Wiley-Blackwell; 2009:1875–1920.
  64. Kindmark H, Sundin A, Granberg D, et al. Endocrine pancreatic

- tumors with glucagon hypersecretion: a retrospective study of 23 cases during 20 years. *Med Oncol*. 2007;24:330–337.
65. van Beek AP, de Haas ER, van Vloten WA, et al. The glucagonoma syndrome and necrolytic migratory erythema: a clinical review. *Eur J Endocrinol*. 2004;151:531–537.
  66. Montenegro F, Lawrence GD, Macon W, et al. Metastatic glucagonoma. improvement after surgical debulking. *Am J Surg*. 1980;139:424–427.
  67. Vinik AI. Glucagonoma syndrome. Diffuse hormonal systems and endocrine tumor syndromes. In: *Neuroendocrine Tumors: A Comprehensive Guide to Diagnosis and Management*. Inglewood, CA: Inter Science Institute; 2004.
  68. Nikou GC, Toubanakis C, Nikolaou P, et al. VIPomas: an update in diagnosis and management in a series of 11 patients. *Hepatogastroenterology*. 2005;52:1259–1265.
  69. Vale W, Rivier C, Brown M. Regulatory peptides of the hypothalamus. *Annu Rev Physiol*. 1977;39:473–527.
  70. Creutzfeldt W, Arnold R. Somatostatin and the stomach: exocrine and endocrine aspects. *Metabolism*. 1978;27:1309–1315.
  71. Ganda OP, Weir GC, Soeldner JS, et al. "Somatostatinoma": a somatostatin-containing tumor of the endocrine pancreas. *N Engl J Med*. 1977;296:963–967.
  72. Krejs GJ, Orci L, Conlon JM, et al. Somatostatinoma syndrome. Biochemical, morphologic and clinical features. *N Engl J Med*. 1979;301:285–292.
  73. Larsson LI, Hirsch MA, Holst JJ, et al. Pancreatic somatostatinoma. Clinical features and physiological implications. *Lancet*. 1977;1:666–668.
  74. Crain EL Jr, Thorn GW. Functioning pancreatic islet cell adenomas; a review of the literature and presentation of two new differential tests. *Medicine (Baltimore)*. 1949;28:427–447.
  75. Fisher RS, Rock E, Levin G, et al. Effects of somatostatin on gallbladder emptying. *Gastroenterology*. 1987;92:885–890.
  76. Axelrod L, Bush MA, Hirsch HJ, et al. Malignant somatostatinoma: clinical features and metabolic studies. *J Clin Endocrinol Metab*. 1981;52:886–896.
  77. Penman E, Wass JA, Besser GM, et al. Somatostatin secretion by lung and thymic tumours. *Clin Endocrinol (Oxf)*. 1980;13:613–620.
  78. Boden G, Baile CA, McLaughlin CL, et al. Effects of starvation and obesity on somatostatin, insulin, and glucagon release from an isolated perfused organ system. *Am J Physiol*. 1981;241:E215–E220.
  79. Creutzfeldt W, Lankisch PG, Folsch UR. Inhibition by somatostatin of pancreatic juice and enzyme secretion and gallbladder contraction in man induced by secretin and cholecystokinin-pancreozymin administration [author's translation]. *Dtsch Med Wochenschr*. 1975;100:1135–1138.
  80. Schwartz TW. Atropine suppression test for pancreatic polypeptide. *Lancet*. 1978;2:43–44.
  81. Bloom SR, Mortimer CH, Thorner MO, et al. Inhibition of gastrin and gastric-acid secretion by growth-hormone release-inhibiting hormone. *Lancet*. 1974;2:1106–1109.
  82. Vinik AI, Shapiro B, Thompson NW. Plasma gut hormone levels in 37 patients with pheochromocytomas. *World J Surg*. 1986;10:593–604.
  83. Bhatena S, Higgins G, Recant L. *Glucagonoma and Glucagonoma Syndrome*. New York: Elsevier; 1981:413.
  84. Vinik AI, Delbridge L, Moattari R, et al. Transhepatic portal vein catheterization for localization of insulinomas: a ten-year experience. *Surgery*. 1991;109:1–11.
  85. Jensen RT, Gardner JD, Raufman JP, et al. Zollinger-Ellison syndrome: current concepts and management. *Ann Intern Med*. 1983;98:59–75.
  86. Vinik AI, Levitt NS, Pimstone BL, et al. Peripheral plasma somatostatin-like immunoreactive responses to insulin hypoglycemia and a mixed meal in healthy subjects and in noninsulin-dependent maturity-onset diabetics. *J Clin Endocrinol Metab*. 1981;52:330–337.
  87. Sano T, Kagawa N, Hizawa K. Demonstration of somatostatin production in medullary carcinoma of the thyroid. *Jpn J Cancer Res*. 1980;10:221.
  88. Saito S, Saito H, Matsumura M, et al. Molecular heterogeneity and biological activity of immunoreactive somatostatin in medullary carcinoma of the thyroid. *J Clin Endocrinol Metab*. 1981;53:1117–1122.
  89. Roos BA, Lindall AW, Eells J, et al. Increased plasma and tumor somatostatin-like immunoreactivity in medullary thyroid carcinoma and small cell lung cancer. *J Clin Endocrinol Metab*. 1981;52:187–194.
  90. Ghose RR, Gupta SK. Oat cell carcinoma of bronchus presenting with somatostatinoma syndrome. *Thorax*. 1981;36:550–551.
  91. Jackson J, Raju U, Janakivamon N. Metastatic pulmonary somatostatinoma presenting with diabetic ketoacidosis: clinical biochemical and morphologic characterization. *Clin Res*. 1986;34:196A.
  92. Berelowitz M, Szabo M, Barowsky HW, et al. Somatostatin-like immunoactivity and biological activity is present in a human pheochromocytoma. *J Clin Endocrinol Metab*. 1983;56:134–138.
  93. Samols E, Weir GC, Ramsey R, et al. Modulation of pancreatic somatostatin by adrenergic and cholinergic agonism and by hyper- and hypoglycemic sulfonamides. *Metabolism*. 1978;27:1219–1221.
  94. Pipeleers D, Couturier E, Gepts W, et al. Five cases of somatostatinoma: clinical heterogeneity and diagnostic usefulness of basal and tolbutamide-induced hypersomatostatinemia. *J Clin Endocrinol Metab*. 1983;56:1236–1242.
  95. Moayedoddin B, Booya F, Wermers RA, et al. Spectrum of malignant somatostatin-producing neuroendocrine tumors. *Endocr Pract*. 2006;12:394–400.
  96. Tanaka S, Yamasaki S, Matsushita H, et al. Duodenal somatostatinoma: a case report and review of 31 cases with special reference to the relationship between tumor size and metastasis. *Pathol Int*. 2000;50:146–152.
  97. Gola M, Doga M, Bonadonna S, et al. Neuroendocrine tumors secreting growth hormone-releasing hormone: pathophysiological and clinical aspects. *Pituitary*. 2006;9:221–229.
  98. Maton PN, Gardner JD, Jensen RT. Cushing's syndrome in patients with the Zollinger-Ellison syndrome. *N Engl J Med*. 1986;315:1–5.
  99. Mao C, Carter P, Schaefer P, et al. Malignant islet cell tumor associated with hypercalcemia. *Surgery*. 1995;117:37–40.
  100. Plockinger U, Wiedenmann B. Diagnosis of non-functioning neuro-endocrine gastro-enteropancreatic tumours. *Neuroendocrinology*. 2004;80(suppl 1):35–38.
  101. Gullo L, Migliori M, Falconi M, et al. Nonfunctioning pancreatic endocrine tumors: a multicenter clinical study. *Am J Gastroenterol*. 2003;98:2435–2439.
  102. Vinik AI, Silva MP, Woltering EA, et al. Biochemical testing for neuroendocrine tumors. *Pancreas*. 2009;38:876–889.
  103. Nieman LK, Biller BM, Findling JW, et al. The diagnosis of Cushing's syndrome: an Endocrine Society Clinical Practice Guideline. *J Clin Endocrinol Metab*. 2008;93:1526–1540.
  104. de Herder WW. Biochemistry of neuroendocrine tumours. *Best Pract Res Clin Endocrinol Metab*. 2007;21:33–41.
  105. Oberg K, Eriksson B. *Best Practice & Research Clinical Endocrinology Metabolism*. Oxford, England: Elsevier, Ltd; 2007.
  106. Ardill JE. Circulating markers for endocrine tumours of the gastroenteropancreatic tract. *Ann Clin Biochem*. 2008;45:539–559.
  107. Lenders JW, Eisenhofer G, Mannelli M, et al. Pheochromocytoma. *Lancet*. 2005;366:665–675.
  108. Manger WM, Gifford RW. Pheochromocytoma. *J Clin Hypertens (Greenwich)*. 2002;4:62–72.
  109. Neumann HP, Bausch B, McWhinney SR, et al. Germ-line mutations in nonsyndromic pheochromocytoma. *N Engl J Med*. 2002;346:1459–1466.
  110. Barontini M, Levin G, Sanso G. Characteristics of pheochromocytoma in a 4- to 20-year-old population. *Ann N Y Acad Sci*. 2006;1073:30–37.
  111. de Krijger RR, Petri BJ, van Nederveen FH, et al. Frequent genetic changes in childhood pheochromocytomas. *Ann N Y Acad Sci*. 2006;1073:166–176.

112. Ludwig AD, Feig DI, Brandt ML, et al. Recent advances in the diagnosis and treatment of pheochromocytoma in children. *Am J Surg.* 2007;194:792–796.
113. Benn DE, Gimenez-Roqueplo AP, Reilly JR, et al. Clinical presentation and penetrance of pheochromocytoma/paraganglioma syndromes. *J Clin Endocrinol Metab.* 2006;91:827–836.
114. Gimenez-Roqueplo AP, Favier J, Rustin P, et al. Mutations in the SDHB gene are associated with extra-adrenal and/or malignant pheochromocytomas. *Cancer Res.* 2003;63:5615–5621.
115. Bryant J, Farmer J, Kessler LJ, et al. Pheochromocytoma: the expanding genetic differential diagnosis. *J Natl Cancer Inst.* 2003;95:1196–1204.
116. Brouwers FM, Eisenhofer G, Tao JJ, et al. High frequency of SDHB germline mutations in patients with malignant catecholamine-producing paragangliomas: implications for genetic testing. *J Clin Endocrinol Metab.* 2006;91:4505–4509.
117. Timmers HJ, Kozupa A, Eisenhofer G, et al. Clinical presentations, biochemical phenotypes, and genotype-phenotype correlations in patients with succinate dehydrogenase subunit B-associated pheochromocytomas and paragangliomas. *J Clin Endocrinol Metab.* 2007;92:779–786.
118. Amar L, Bertherat J, Baudin E, et al. Genetic testing in pheochromocytoma or functional paraganglioma. *J Clin Oncol.* 2005;23:8812–8818.
119. Lenders JW, Pacak K, Walther MM, et al. Biochemical diagnosis of pheochromocytoma: which test is best? *JAMA.* 2002;287:1427–1434.
120. Eisenhofer G, Lenders JW, Linehan WM, et al. Plasma normetanephrine and metanephrine for detecting pheochromocytoma in von Hippel-Lindau disease and multiple endocrine neoplasia type 2. *N Engl J Med.* 1999;340:1872–1879.
121. Sawka AM, Jaeschke R, Singh RJ, et al. A comparison of biochemical tests for pheochromocytoma: measurement of fractionated plasma metanephrines compared with the combination of 24-hour urinary metanephrines and catecholamines. *J Clin Endocrinol Metab.* 2003;88:553–558.
122. Lenders JW, Willemsen JJ, Eisenhofer G, et al. Is supine rest necessary before blood sampling for plasma metanephrines? *Clin Chem.* 2007;53:352–354.
123. Grossman A, Pacak K, Sawka A, et al. Biochemical diagnosis and localization of pheochromocytoma: can we reach a consensus? *Ann N Y Acad Sci.* 2006;1073:332–347.
124. Eisenhofer G, Goldstein DS, Walther MM, et al. Biochemical diagnosis of pheochromocytoma: how to distinguish true- from false-positive test results. *J Clin Endocrinol Metab.* 2003;88:2656–2666.
125. Guller U, Turek J, Eubanks S, et al. Detecting pheochromocytoma: defining the most sensitive test. *Ann Surg.* 2006;243:102–107.
126. Giovannella L, Squin N, Ghelfo A, et al. Chromogranin A immunoradiometric assay in diagnosis of pheochromocytoma: comparison with plasma metanephrines and <sup>123</sup>I-MIBG scan. *Q J Nucl Med Mol Imaging.* 2006;50:344–347.
127. Bilek R, Safarik L, Ciprova V, et al. Chromogranin A, a member of neuroendocrine secretory proteins as a selective marker for laboratory diagnosis of pheochromocytoma. *Physiol Res.* 2008;57(suppl 1):S171–S179.
128. Klein RD, Lloyd RV, Young WF. Hereditary Paraganglioma-Pheochromocytoma Syndromes. *Gene Rev.* 2008.
129. Algeciras-Schimmich A, Preissner CM, Young WF Jr, et al. Plasma chromogranin A or urine fractionated metanephrines follow-up testing improves the diagnostic accuracy of plasma fractionated metanephrines for pheochromocytoma. *J Clin Endocrinol Metab.* 2008;93:91–95.
130. Young WF Jr. Paragangliomas: clinical overview. *Ann N Y Acad Sci.* 2006;1073:21–29.
131. Costante G, Meringolo D, Durante C, et al. Predictive value of serum calcitonin levels for preoperative diagnosis of medullary thyroid carcinoma in a cohort of 5817 consecutive patients with thyroid nodules. *J Clin Endocrinol Metab.* 2007;92:450–455.
132. Cohen R, Campos JM, Salaun C, et al. Preoperative calcitonin levels are predictive of tumor size and postoperative calcitonin normalization in medullary thyroid carcinoma. Groupe d'Etudes des Tumeurs a Calcitonine (GETC). *J Clin Endocrinol Metab.* 2000;85:919–922.
133. Kebebew E, Ituarte PH, Siperstein AE, et al. Medullary thyroid carcinoma: clinical characteristics, treatment, prognostic factors, and a comparison of staging systems. *Cancer.* 2000;88:1139–1148.
134. Etit D, Faquin WC, Gaz R, et al. Histopathologic and clinical features of medullary microcarcinoma and C-cell hyperplasia in prophylactic thyroidectomies for medullary carcinoma: a study of 42 cases. *Arch Pathol Lab Med.* 2008;132:1767–1773.
135. Elisei R. Routine serum calcitonin measurement in the evaluation of thyroid nodules. *Best Pract Res Clin Endocrinol Metab.* 2008;22:941–953.
136. Scheuba C, Kaserer K, Moritz A, et al. Sporadic hypercalcitoninemia: clinical and therapeutic consequences. *Endocr Relat Cancer.* 2009;16:243–253.
137. Colombo P, Locatelli F, Travaglini P. Useful and limits of the biochemical markers for the diagnosis of thyroid carcinoma [in Italian]. *Ann Ital Chir.* 2006;77:209–214.
138. Schley E, Shin S, Nakave AA, et al. Symptomatic isolated C-cell hyperplasia: masquerading as carcinoid syndrome. *Pancreas.* 2009 submitted.
139. Marx SJ, Agarwal SK, Kester MB, et al. Multiple endocrine neoplasia type 1: clinical and genetic features of the hereditary endocrine neoplasias. *Recent Prog Horm Res.* 1999;54:397–438.
140. Piecha G, Chudek J, Wiecek A. Multiple endocrine neoplasia type 1. *Eur J Intern Med.* 2008;19:99–103.
141. Perry R. Multiple endocrine neoplasia type 1 and MEN II. Diffuse hormonal systems and endocrine tumor syndromes. 2006.
142. Brandi ML, Gagel RF, Angeli A, et al. Guidelines for diagnosis and therapy of MEN type 1 and type 2. *J Clin Endocrinol Metab.* 2001;86:5658–5671.
143. Gertner ME, Kebebew E. Multiple endocrine neoplasia type 2. *Curr Treat Options Oncol.* 2004;5:315–325.
144. Fialkowski EA, DeBenedetti MK, Moley JF, et al. RET proto-oncogene testing in infants presenting with Hirschsprung disease identifies 2 new multiple endocrine neoplasia 2A kindreds. *J Pediatr Surg.* 2008;43:188–190.
145. Raue F, Frank-Raue K. Multiple endocrine neoplasia type 2: 2007 update. *Horm Res.* 2007;68(suppl 5):101–104.
146. Taupenot L, Harper KL, O'Connor DT. The chromogranin-secretogranin family. *N Engl J Med.* 2003;348:1134–1149.
147. Nobels FR, Kwekkeboom DJ, Bouillon R, et al. Chromogranin A: its clinical value as marker of neuroendocrine tumours. *Eur J Clin Invest.* 1998;28:431–440.
148. Stridsberg M, Eriksson B, Fellstrom B, et al. Measurements of chromogranin B can serve as a complement to chromogranin A. *Regul Pept.* 2007;139:80–83.
149. Takiyuddin MA, Cervenka JH, Hsiao RJ, et al. Storage and release in hypertension. *Hypertension.* 1990;15:237–246.
150. Oberg K. Biochemical diagnosis of neuroendocrine GEP tumor. *Yale J Biol Med.* 1997;70:501–508.
151. Nobels FR, Kwekkeboom DJ, Coopmans W, et al. Chromogranin A as serum marker for neuroendocrine neoplasia: comparison with neuron-specific enolase and the alpha-subunit of glycoprotein hormones. *J Clin Endocrinol Metab.* 1997;82:2622–2628.
152. Zatelli MC, Torta M, Leon A, et al. Chromogranin A as a marker of neuroendocrine neoplasia: an Italian Multicenter Study. *Endocr Relat Cancer.* 2007;14:473–482.
153. Panzuto F, Severi C, Cannizzaro R, et al. Utility of combined use of plasma levels of chromogranin A and pancreatic polypeptide in the diagnosis of gastrointestinal and pancreatic endocrine tumors. *J Endocrinol Invest.* 2004;27:6–11.
154. Jensen EH, Kvols L, McLoughlin JM, et al. Biomarkers predict outcomes following cytoreductive surgery for hepatic metastases from functional carcinoid tumors. *Ann Surg Oncol.* 2007;14:780–785.

155. Stronge RL, Turner GB, Johnston BT, et al. A rapid rise in circulating pancreastatin in response to somatostatin analogue therapy is associated with poor survival in patients with neuroendocrine tumours. *Ann Clin Biochem*. 2008;45:560–566.
156. Bloomston M, Al-Saif O, Klemanski D, et al. Hepatic artery chemoembolization in 122 patients with metastatic carcinoid tumor: lessons learned. *J Gastrointest Surg*. 2007;11:264–271.
157. Turner GB, Johnston BT, McCance DR, et al. Circulating markers of prognosis and response to treatment in patients with midgut carcinoid tumours. *Gut*. 2006;55:1586–1591.
158. Lipton A, Costa L, Ali S, et al. Use of markers of bone turnover for monitoring bone metastases and the response to therapy. *Semin Oncol*. 2001;28:54–59.
159. Brown JE, Cook RJ, Major P, et al. Bone turnover markers as predictors of skeletal complications in prostate cancer, lung cancer, and other solid tumors. *J Natl Cancer Inst*. 2005;97:59–69.
160. Roberts WC. A unique heart disease associated with a unique cancer: carcinoid heart disease. *Am J Cardiol*. 1997;80:251–256.
161. Fox DJ, Khattar RS. Carcinoid heart disease: presentation, diagnosis, and management. *Heart*. 2004;90:1224–1228.
162. Bhattacharyya S, Toumpanakis C, Caplin ME, et al. Usefulness of N-terminal pro-brain natriuretic peptide as a biomarker of the presence of carcinoid heart disease. *Am J Cardiol*. 2008;102:938–942.
163. Rockall AG, Reznick RH. Imaging of neuroendocrine tumours (CT/MR/US). *Best Pract Res Clin Endocrinol Metab*. 2007;21:43–68.
164. Gibril F, Reynolds JC, Lubensky IA, et al. Ability of somatostatin receptor scintigraphy to identify patients with gastric carcinoids: a prospective study. *J Nucl Med*. 2000;41:1646–1656.
165. Semelka RC, Custodio CM, Cem BN, et al. Neuroendocrine tumors of the pancreas: spectrum of appearances on MRI. *J Magn Reson Imaging*. 2000;11:141–148.
166. Pamuklar E, Semelka RC. MR imaging of the pancreas. *Magn Reson Imaging Clin N Am*. 2005;13:313–330.
167. Kelekis NL, Semelka RC. MRI of pancreatic tumors. *Eur Radiol*. 1997;7:875–886.
168. Dromain C, de BT, Baudin E, et al. MR imaging of hepatic metastases caused by neuroendocrine tumors: comparing four techniques. *AJR Am J Roentgenol*. 2003;180:121–128.
169. Debray MP, Geoffroy O, Laissy JP, et al. Imaging appearances of metastases from neuroendocrine tumours of the pancreas. *Br J Radiol*. 2001;74:1065–1070.
170. Krenning EP, Kooij PP, Bakker WH, et al. Radiotherapy with a radiolabeled somatostatin analogue, [<sup>111</sup>In-DTPA-D-Phe<sup>1</sup>]-octreotide. A case history. *Ann N Y Acad Sci*. 1994;733:496–506.
171. Orlefors H, Sundin A, Garske U, et al. Whole-body (111)C-5-hydroxytryptophan positron emission tomography as a universal imaging technique for neuroendocrine tumors: comparison with somatostatin receptor scintigraphy and computed tomography. *J Clin Endocrinol Metab*. 2005;90:3392–3400.
172. Noone TC, Hosey J, Firat Z, et al. Imaging and localization of islet-cell tumours of the pancreas on CT and MRI. *Best Pract Res Clin Endocrinol Metab*. 2005;19:195–211.
173. Kloppel G, Couvelard A, Perren A, et al. ENETS guidelines for the standards of care in patients with neuroendocrine tumors: towards a standardized approach to the diagnosis of gastroenteropancreatic neuroendocrine tumors and their prognostic stratification. *Neuroendocrinology*. 2008 Dec 5. [Epub ahead of print]
174. Virgolini I, Traub-Weidinger T, Decristoforo C. Nuclear medicine in the detection and management of pancreatic islet-cell tumours. *Best Pract Res Clin Endocrinol Metab*. 2005;19:213–227.
175. Gibril F, Jensen RT. Diagnostic uses of radiolabelled somatostatin receptor analogues in gastroenteropancreatic endocrine tumours. *Dig Liver Dis*. 2004;36(suppl 1):S106–S120.
176. Sundin A, Garske U, Orlefors H. Nuclear imaging of neuroendocrine tumours. *Best Pract Res Clin Endocrinol Metab*. 2007;21:69–85.
177. Norton JA, Jensen RT. Resolved and unresolved controversies in the surgical management of patients with Zollinger-Ellison syndrome. *Ann Surg*. 2004;240:757–773.
178. McLean AM, Fairclough PD. Endoscopic ultrasound in the localisation of pancreatic islet cell tumours. *Best Pract Res Clin Endocrinol Metab*. 2005;19:177–193.
179. Doppman JL, Miller DL, Chang R, et al. Gastrinomas: localization by means of selective intraarterial injection of secretin. *Radiology*. 1990;174:25–29.
180. Doppman JL, Chang R, Fraker DL, et al. Localization of insulinomas to regions of the pancreas by intra-arterial stimulation with calcium. *Ann Intern Med*. 1995;123:269–273.
181. Strader D, Doppman J, Orbuch M, et al. Functional localization of pancreatic endocrine tumors. In: Mignon M, Jensen RT, eds. *In Endocrine Tumors of the Pancreas: Recent Advances in Research and Management. Series: Frontiers of Gastrointestinal Research*. Basel, Switzerland: Karger Publishing Co; 1995:282–297.
182. Norton JA. Surgical treatment of islet cell tumors with special emphasis on operative tumors. In: Mignon M, Jensen RT, eds. *In Endocrine Tumors of the Pancreas: Recent Advances in Research and Management*. Basel, Switzerland: S. Karger; 1995: 309–332.
183. Shin LK, Brant-Zawadzki G, Kamaya A, et al. Intraoperative ultrasound of the pancreas. *Ultrasound Q*. 2009;25:39–48.
184. Gabriel M, Decristoforo C, Kendler D, et al. <sup>68</sup>Ga-DOTA-Tyr<sup>3</sup>-octreotide PET in neuroendocrine tumors: comparison with somatostatin receptor scintigraphy and CT. *J Nucl Med*. 2007;48:508–518.
185. Eriksson B, Orlefors H, Oberg K, et al. Developments in PET for the detection of endocrine tumours. *Best Pract Res Clin Endocrinol Metab*. 2005;19:311–324.
186. Jackson JE. Angiography and arterial stimulation venous sampling in the localization of pancreatic neuroendocrine tumours. *Best Pract Res Clin Endocrinol Metab*. 2005;19:229–239.
187. Sundin A, Vullierme MP, Kaltsas G, et al. ENETS guidelines for the standards of care in patients with neuroendocrine tumours: radiological examinations in patients with neuroendocrine tumours. *Neuroendocrinology*. 2009;90:167–183.
188. Krenning EP, Kwekkeboom DJ, Oei HY, et al. Somatostatin-receptor scintigraphy in gastroenteropancreatic tumors. An overview of European results. *Ann N Y Acad Sci*. 1994;733:416–424.
189. Gibril F, Reynolds JC, Doppman JL, et al. Somatostatin receptor scintigraphy: its sensitivity compared with that of other imaging methods in detecting primary and metastatic gastrinomas. A prospective study. *Ann Intern Med*. 1996;125:26–34.
190. Termanini B, Gibril F, Reynolds JC, et al. Value of somatostatin receptor scintigraphy: a prospective study in gastrinoma of its effect on clinical management. *Gastroenterology*. 1997;112:335–347.
191. Berna M, Jensen R. Use of radiolabeled somatostatin receptor analogues in diagnosis of gastrointestinal neuroendocrine tumors. In: Modlin IM, Oberg K, eds. *A Century of Advances in Neuroendocrine Tumor Biology and Treatment*. Hanover: Felstein C.C.C.P.; 2007:328–339.
192. Gibril F, Reynolds JC, Chen CC, et al. Specificity of somatostatin receptor scintigraphy: a prospective study and effects of false-positive localizations on management in patients with gastrinomas. *J Nucl Med*. 1999;40:539–553.
193. Hellman P, Hennings J, Akerstrom G, et al. Endoscopic ultrasonography for evaluation of pancreatic tumours in multiple endocrine neoplasia type 1. *Br J Surg*. 2005;92:1508–1512.
194. Libutti SK, Choyke PL, Bartlett DL, et al. Pancreatic neuroendocrine tumors associated with von Hippel Lindau disease: diagnostic and management recommendations. *Surgery*. 1998;124:1153–1159.
195. Langer P, Kann PH, Fendrich V, et al. Prospective evaluation of imaging procedures for the detection of pancreaticoduodenal endocrine tumors in patients with multiple endocrine neoplasia type 1. *World J Surg*. 2004;28:1317–1322.
196. Manfredi S, Pagenault M, de Lajarte-Thirouard AS, et al. Type 1 and 2 gastric carcinoid tumors: long-term follow-up of the efficacy of treatment with a slow-release somatostatin analogue. *Eur J Gastroenterol Hepatol*. 2007;19:1021–1025.

197. Gibril F, Doppman JL, Chang R, et al. Metastatic gastrinomas: localization with selective arterial injection of secretin. *Radiology*. 1996;198:77–84.
198. Frucht H, Norton JA, London JF, et al. Detection of duodenal gastrinomas by operative endoscopic transillumination. A prospective study. *Gastroenterology*. 1990;99:1622–1627.
199. Norton JA, Doppman JL, Jensen RT. Curative resection in Zollinger-Ellison syndrome. Results of a 10-year prospective study. *Ann Surg*. 1992;215:8–18.
200. Norton JA, Alexander HR, Fraker DL, et al. Does the use of routine duodenotomy (DUODX) affect rate of cure, development of liver metastases, or survival in patients with Zollinger-Ellison syndrome? *Ann Surg*. 2004;239:617–625.
201. Sugg SL, Norton JA, Fraker DL, et al. A prospective study of intraoperative methods to diagnose and resect duodenal gastrinomas. *Ann Surg*. 1993;218:138–144.
202. Pacak K, Eisenhofer G, Goldstein DS. Functional imaging of endocrine tumors: role of positron emission tomography. *Endocr Rev*. 2004;25:568–580.
203. Lumachi F, Tregnaigh A, Zucchetto P, et al. Sensitivity and positive predictive value of CT, MRI and <sup>123</sup>I-MIBG scintigraphy in localizing pheochromocytomas: a prospective study. *Nucl Med Commun*. 2006;27:583–587.
204. van der HE, de Herder WW, Bruining HA, et al. [(123)I]metaiodobenzylguanidine and [(111)In]octreotide uptake in benign and malignant pheochromocytomas. *J Clin Endocrinol Metab*. 2001;86:685–693.
205. Bhatia KS, Ismail MM, Sahdev A, et al. <sup>123</sup>I-metaiodobenzylguanidine (MIBG) scintigraphy for the detection of adrenal and extra-adrenal pheochromocytomas: CT and MRI correlation. *Clin Endocrinol (Oxf)*. 2008;69:181–188.
206. Mackenzie IS, Gurnell M, Balan KK, et al. The use of 18-fluoro-dihydroxyphenylalanine and 18-fluorodeoxyglucose positron emission tomography scanning in the assessment of metaiodobenzylguanidine-negative pheochromocytoma. *Eur J Endocrinol*. 2007;157:533–537.
207. Ilias I, Yu J, Carrasquillo JA, et al. Superiority of 6-[<sup>18</sup>F]-fluorodopamine positron emission tomography versus [<sup>131</sup>I]-metaiodobenzylguanidine scintigraphy in the localization of metastatic pheochromocytoma. *J Clin Endocrinol Metab*. 2003;88:4083–4087.
208. Hoegerle S, Nitzsche E, Althoefer C, et al. Pheochromocytomas: detection with <sup>18</sup>F DOPA whole body PET—initial results. *Radiology*. 2002;222:507–512.
209. Timmers HJ, Hadi M, Carrasquillo JA, et al. The effects of carbidopa on uptake of 6-<sup>18</sup>F-fluoro-L-DOPA in PET of pheochromocytoma and extraadrenal abdominal paraganglioma. *J Nucl Med*. 2007;48:1599–1606.
210. Shulkin BL, Koeppe RA, Francis IR, et al. Pheochromocytomas that do not accumulate metaiodobenzylguanidine: localization with PET and administration of FDG. *Radiology*. 1993;186:711–715.
211. Shulkin BL, Thompson NW, Shapiro B, et al. Pheochromocytomas: imaging with 2-[fluorine-18]fluoro-2-deoxy-D-glucose PET. *Radiology*. 1999;212:35–41.
212. Timmers HJ, Kozupa A, Chen CC, et al. Superiority of fluorodeoxyglucose positron emission tomography to other functional imaging techniques in the evaluation of metastatic SDHB-associated pheochromocytoma and paraganglioma. *J Clin Oncol*. 2007;25:2262–2269.
213. Wild D, Macke H, Christ E, et al. Glucagon-like peptide 1-receptor scans to localize occult insulinomas. *N Engl J Med*. 2008;359:766–768.
214. Modlin IM, Oberg K, Chung DC, et al. Gastroenteropancreatic neuroendocrine tumours. *Lancet Oncol*. 2008;9:61–72.